

# *RET* Proto-Oncogene: A Review and Update of Genotype–Phenotype Correlations in Hereditary Medullary Thyroid Cancer and Associated Endocrine Tumors

Maria A. Kouvaraki,<sup>1</sup> Suzanne E. Shapiro,<sup>1</sup> Nancy D. Perrier,<sup>1</sup> Gilbert J. Cote,<sup>2</sup> Robert F. Gagel,<sup>2</sup>  
Ana O. Hoff,<sup>2</sup> Steven I. Sherman,<sup>2</sup> Jeffrey E. Lee,<sup>1</sup> and Douglas B. Evans<sup>1</sup>

Hereditary medullary thyroid carcinoma (MTC) is caused by autosomal dominant gain-of-function mutations in the *RET* proto-oncogene. Associations between specific *RET* mutations (genotype) and the aggressiveness of MTC and presence or absence of other endocrine neoplasms (phenotype) are well documented. Mutations in six exons (10, 11, 13, 14, 15, and 16) located in either cysteine-rich or tyrosine kinase domains cause one of three distinctive clinical subtypes: familial MTC, multiple endocrine neoplasia (MEN) type 2A (including variants with Hirschsprung's disease and cutaneous lichen amyloidosis), and MEN 2B. Hallmarks of MEN 2A include MTC, pheochromocytoma, and hyperparathyroidism. MEN 2B is associated with an earlier onset of MTC and pheochromocytoma, the absence of hyperparathyroidism, and the presence of striking physical stigmata (e.g., coarse facies, ganglioneuromatosis, and marfanoid habitus). Familial MTC is not associated with other endocrine neoplasms; however, the accurate distinction between familial MTC and MEN 2A may be difficult in kindreds with small size, incomplete histories, or a predominance of young individuals who may not have yet fully manifested the syndrome. Genetic testing detects greater than 95% of mutation carriers and is considered the standard of care for all first-degree relatives of patients with newly diagnosed MTC. Recommendations on the timing of prophylactic thyroidectomy and the extent of surgery are based upon a model that utilizes genotype–phenotype correlations to stratify mutations into three risk levels.

## Introduction

**M**EDULLARY THYROID CARCINOMA (MTC) is a rare calcitonin (CT)-producing tumor first described in 1959 by Hazard et al. (1). This neoplasm arises from the parafollicular C cells of the thyroid gland, which are derived embryologically from the neural crest. Of the 23,600 new cases of thyroid cancer expected during 2004 in the United States, MTC represents only 3% to 10% (2–4). Most patients with MTC have sporadic (nonfamilial) disease, with hereditary MTC accounting for 25% to 30% of cases. Hereditary MTC is usually bilateral and multicentric, whereas a unilateral and single focus of MTC is commonly found in sporadic cases. Multifocal C-cell hyperplasia is considered to be a precursor to invasive MTC in patients with hereditary disease (5).

Hereditary MTC is a consistent feature of multiple endocrine neoplasia (MEN) type 2. MEN 2 is a genetic syndrome caused by germline mutations in the *RET* proto-oncogene, is transmitted in an autosomal dominant pattern, and affects

approximately 1 in 30,000 individuals (6–8). At present, more than 500 kindreds with MEN 2 have been recognized worldwide (9). Hereditary MTC is divided into three clinical subtypes depending on the presence or absence of tissue-specific tumors, phenotypic characteristics, and the number of affected family members (Table 1). MEN 2A, or Sipple's syndrome, is the most common subtype (approximately 80% to 90% of patients with hereditary MTC) and is characterized by MTC (100% of affected individuals), pheochromocytoma (50%), and primary hyperparathyroidism (HPT; 20%) (10). Sipple (11) first reported the association of MTC with pheochromocytoma in 1961; however, the term "multiple endocrine neoplasia type 2" was first used by Steiner et al. (12), who associated the presence of primary HPT with the syndrome (12). Hereditary MTC has full penetrance in all clinical subtypes and is usually the first manifestation of the syndrome (13,14). Patients with MEN 2A may manifest MTC as early as age 5 years and C-cell hyperplasia at an earlier age. However, when a diagnosis of MEN 2A has not yet been es-

<sup>1</sup>Departments of Surgical Oncology and <sup>2</sup>Endocrine Neoplasia and Hormonal Disorders, The University of Texas M. D. Anderson Cancer Center, Houston, Texas.

TABLE 1. CLASSIFICATION OF HEREDITARY MEDULLARY THYROID CARCINOMA

Subtype	MTC (Penetrance)	Pheochromocytoma (Penetrance)	HPT (Penetrance)	No. of affected family members
MEN 2A <sup>a</sup>	Yes (100%)	Yes (50%)	Yes (20%)	Any
MEN 2B <sup>b</sup>	Yes (100%)	Yes (50%)	No	Any
FMTC	Yes (100%)	No	No	≥4
Unclassified	Yes (100%)	No	No	≤3

<sup>a</sup>Diagnosis of pheochromocytoma and/or HPT is required.

<sup>b</sup>Characteristic mucosal neuromas on the tongue, lips, subconjunctival areas, and gastrointestinal tract are required.

FMTC, familial medullary thyroid carcinoma; HPT, hyperparathyroidism; MEN, multiple endocrine neoplasia; MTC, medullary thyroid carcinoma.

established within a family, newly diagnosed patients typically present with a thyroid nodule or neck mass by the age of 15 to 20 years. In the era before the identification of the *RET* gene as the cause of hereditary MTC clinical screening for hereditary MTC consisted of measurements of basal and stimulated plasma CT levels. Unfortunately, CT is not always an accurate marker of MTC because levels of this hormone may also be elevated in patients with C-cell hyperplasia and in patients without MTC who have normal thyroid glands (15,16).

HPT in MEN 2A may be caused by a single adenoma or diffuse hyperplasia of all parathyroid glands. HPT may be associated with symptoms of hypercalcemia or may be subclinical in the setting of mild elevations in serum levels of calcium and parathyroid hormone.

Two rare variants of MEN 2A have been described, one with Hirschsprung's disease (HSCR) and the other with cutaneous lichen amyloidosis (CLA) (17–19). HSCR is caused by the absence of autonomic ganglia in the terminal hindgut, which results in colonic dilatation, obstipation, constipation, and obstruction in neonates. CLA is a pruritic lichenoid skin lesion, usually located on the upper back. Each of these rare variants has been associated only with specific *RET* mutations in patients with MEN 2A.

MEN 2B is less common than MEN 2A, accounting for approximately 5% of MEN 2 cases. It is characterized by aggressive MTC (100%); pheochromocytoma (50%); marfanoid habitus; the presence of distinctive mucosal neuromas on the tongue, lips, and subconjunctival areas; and diffuse ganglioneuromas of the gastrointestinal tract (10,20). HPT is not known to develop in patients with MEN 2B. The MEN 2B phenotype may be recognized during infancy by the characteristic neuromas. MTC in the setting of MEN 2B develops earlier and has a more aggressive course compared with MTC in other MEN 2 variants. The majority of cases of MEN 2B are the result of spontaneous new *RET* mutations, which are not inherited from either parent; therefore, most patients with MEN 2B lack a family history of the disease and thus would not otherwise be targeted to undergo early screening and prophylactic thyroidectomy. As such, these MEN 2B patients often experience a delay in diagnosis until signs of mucosal neuromas and/or palpable thyroid tumors are obvious.

Pheochromocytoma is present in approximately 50% of patients with MEN 2 and is usually diagnosed after MTC, although it precedes the MTC diagnosis in up to 10% of patients, particularly those without an established family history of MEN 2. MEN 2-related pheochromocytomas may be

unilateral but are more commonly bilateral (up to 78%) (21). They are also frequently multicentric and may be associated with extratumoral medullary hyperplasia (22). In contrast, sporadic pheochromocytomas are usually solitary and unilateral, and the extratumoral medulla is normal (22). MEN 2-related pheochromocytomas occur at a younger age than sporadic tumors and are usually benign; however, malignant transformation occurs in up to 4% of patients (23–26). Pheochromocytoma is highly likely in any at-risk patient found to have elevated plasma levels of free metanephrines.

Familial MTC (FMTC), the third clinical subtype of inherited MTC, accounts for 5% to 15% of hereditary MTC cases. It is defined as the presence of MTC in kindreds with four or more affected members and with objective evidence of the absence of adrenal and parathyroid gland involvement (27). FMTC represents a less aggressive form of hereditary MTC, and it has a corresponding older age at onset—often between 20 and 40 years—compared to MEN 2A and MEN 2B (28).

Unclassified cases of suspected hereditary MTC include those with three or fewer affected family members. In such patients, it is often difficult to accurately distinguish between FMTC and MEN 2A because the kindreds may have few individuals, incomplete histories, or a predominance of young individuals who may not have reached the age of full penetrance of pheochromocytoma and/or HPT.

Strong genotype–phenotype correlations in MEN 2 have repeatedly been described, and as expected, the aggressiveness of MTC is influenced by the specific *RET* mutation. For instance, MTC has been confirmed in thyroidectomy specimens from MEN 2A patients as young as 17 months (29), and cervical lymph node metastases have been found in MEN 2B patients as young as 3 years (30). Therefore, identification of the specific *RET* mutation in at-risk patients allows for effective clinical screening and optimal clinical and surgical management (31).

## ***RET* Proto-Oncogene**

### *Biology and physiology*

The *RET* gene is located on chromosome 10q11.2 near the centromere and includes 21 exons. Takahashi et al. (32) first identified *RET* (REarranged during Transfection) in 1985 as a proto-oncogene that can undergo activation by cytogenic rearrangement (32). Three years later, the *RET* gene was cloned by the same investigators (33). The *RET* gene encodes a plasma membrane-bound tyrosine kinase enzyme, the RET receptor, which is expressed by neuroendocrine and neural cells, including thyroid C cells, adrenal medullary cells,

parasympathetic, sympathetic, and colonic ganglia, cells of the urogenital tract, and parathyroid cells derived from branchial arches (32–35). The RET protein consists of an N-terminal signal peptide, an extracellular region (four cadherin-like repeats, a calcium binding site, and a cysteine-rich domain), a transmembrane domain, and two intracellular tyrosine kinase domains. The extracellular cadherin-like domains are important for cell-cell signaling, whereas the cysteine-rich extracellular domain is important for receptor dimerization. The C-terminal tail of RET shows three different splicing variants that produce three protein isoforms with 9 (RET9; short isoform), 43 (RET43; middle isoform), or 51 (RET51; long isoform) distinct amino acids at their C termini (36,37). The three isoforms have physiologically different roles in the development of the kidneys, enteric ganglia, and sympathetic and sensory neuronal cells, as demonstrated by *in situ* hybridization studies (38). Studies in mice with just one isoform have shown that only the short isoform, RET9, is necessary for kidney morphogenesis and gut nervous system development (39,40). However, the long isoform, RET51, participates in kidney differentiation by promoting the survival and tubulogenesis of inner-medullary collecting duct cells in mice (40). In addition, RET51 is required for the metabolism and growth of mature sympathetic neurons (41). The short and long isoforms also activate different signaling pathways in neurons (42).

To date, four ligands for the RET receptor have been identified (43,44). These ligands are the glial cell line-derived neurotrophic factor (GDNF), neurturin, artemin, and persephin (45–48). The RET signal starts from a multimetric complex composed of the RET receptor and one of four different high-affinity glycosyl-phosphatidylinositol-anchored co-receptors, termed GDNF family receptor- $\alpha$  (GFR- $\alpha$ ) 1 to 4 (49). It has been demonstrated that the four RET ligands GDNF, neurturin, persephin, and artemin interact preferentially with GFR- $\alpha$ 1, GFR- $\alpha$ 2, GFR- $\alpha$ 3, and GFR- $\alpha$ 4, respectively (45,50,51). Takahashi (38) and Airaksinen et al. (52) have extensively reviewed the physiologic functions of the GDNF family ligands and their receptors. Signaling requires GDNF-induced RET receptor dimerization, which results in tyrosine autophosphorylation of the receptor intracellular domain on specific tyrosine residues. The RET C-terminal end contains 16 tyrosine residues, and the long isoform, RET51, displays two extra tyrosine residues in its C terminal. Among these tyrosine residues, Y1062 is a multidocking site that interacts with a number of transduction molecules including SHC, FRS2, DOK4/5, IRS1/2, and Enigma. The RET receptor may activate various signaling pathways, mainly through Y1062, including the RES/extracellular signal-regulated kinase, phosphatidylinositol-3 kinase/AKT, p38/MAPK, and JNK pathways (53–66). The GDNF/RET signaling pathway has been reviewed by Ichihara et al. (67), Takahashi (38), and Airaksinen et al. (52).

#### Germline and somatic mutations

Germline mutations of RET causing inactivation (loss of function) are associated with congenital megacolon or HSCR, whereas germline point mutations causing RET activation (gain of function) are responsible for tumor syndromes including MEN 2 and its variants (68–79). Because RET is a proto-oncogene, a single activating mutation of one allele is

sufficient to cause neoplastic transformation. The germline mutations in MEN 2 are usually located either in the extracellular cysteine-rich region (exons 10 and 11) of the RET protein, leading to RET receptor homodimerization, or in the intracellular tyrosine kinase domains (exons 13 to 16), which activate the catalytic site of the RET kinase enzyme that alters substrate specificity (80–82). The first RET germline mutations were identified in 1993 in patients with MEN 2A and FMTC (6,7).

Nonhereditary somatic rearrangements in RET have been identified in papillary thyroid carcinoma. The RET rearrangement in papillary thyroid carcinoma is typically created by an inversion within the chromosome with one breakpoint occurring in intron 11. This rearrangement creates a chimeric gene in which the RET promoter and extracellular domain are replaced by one of several genes. The result is that thyroid follicular cells aberrantly express the tyrosine kinase region of RET (38).

Somatic RET mutations at codons 608, 611, 618, 629, 630, 634, 639, 641, 918, or 922 are found in approximately 25% of patients with sporadic MTC, with mutations at codon 918 occurring most frequently (81–89). As with germline 918 mutations, the somatic 918 mutations are associated with aggressive MTC behavior (9,90).


Somatic RET mutations have also been reported in patients with sporadic pheochromocytoma; these include mutations at codons 630, 634, and 918 and an exon 9 splice donor site mutation (91–95).

Some activating germline RET mutations are associated with MTC only when they are present in a homozygous state, indicating that these particular RET mutations may express a low transforming activity (96). Recently, Elisei et al. (96) reported a patient with apparently sporadic MTC who was homozygous for a germline point mutation (A883T) in exon 15 of the RET gene. This index patient had histologically confirmed MTC and C-cell hyperplasia, whereas all heterozygous relatives lacked any clinical and/or biochemical signs of MTC.

Polymorphic variants and ancestral haplotypes of RET, which have a low penetrance, have been identified in a subset of patients with apparently sporadic MTC, sporadic pheochromocytomas, or isolated (nonfamilial) HSCR (97–100). For example, the rare GGICC haplotype (SNP14, 2508C  $\rightarrow$  [S836S]) is characterized by reduced penetrance and a low frequency among patients with isolated HSCR but is overrepresented in individuals with sporadic MTC (99). Furthermore, McWhinney et al. (97) found that an ancestral haplotype of RET (IVS1 SNP polymorphism) is overrepresented in patients with apparently sporadic pheochromocytomas and may also have the ability to modulate the age at onset of such tumors.

#### Genotype-Phenotype Correlations

More than 95% of families with MEN 2 have a germline mutation in the RET proto-oncogene. The specific RET codon mutation correlates with the phenotypic expression of hereditary MTC (Fig. 1). Moreover, particular mutations correlate with the aggressiveness of MTC, and this association is more predictable within a given family (9,101). There are examples of mutations in some FMTC families with no known cases of MTC-related death, whereas the same mutations in



**FIG. 1.** Correlation of specific *RET* codon mutations with the phenotypic expression of hereditary MTC. \*Development of pheochromocytoma has not been reported. †Because of the small number of reported patients the distinction between MEN 2A and familial medullary thyroid carcinoma (FMTC) cannot be made.

other families correlate with aggressive MTC and have led to MTC-related deaths (102). This observation suggests that other environmental or genetic mechanisms also affect the biologic aggressiveness of MTC.

Mutations at codons 609, 611, 618, and 620 (extracellular cysteine-rich region, exon 10) are responsible for 10% to 15% of cases of MEN 2A and to date for all cases of MEN 2A/HSCR. A codon 634 (extracellular cysteine-rich region, exon 11) mutation has been found in approximately 85% of patients with MEN 2A and in all cases of MEN 2A/CLA (10,103). However, not all patients with codon 634 mutations develop CLA, and not all patients with CLA have been found to carry *RET* mutations. The underlying pathophysiology of CLA may be related to a sensory abnormality in the C6-T6 dermatomes resulting in pruritus and chronic irritation (104,105). HPT, which occurs in 20% of patients with MEN 2A, is also associated most commonly with codon 634 mutations and less frequently with mutations in codons 609, 611, 618, 620, 790, and 791 (106). The C634R mutation specifically correlates with a higher risk of HPT (103). Rare mutations that are associated with MEN 2A include those at codons 635 and 637 (exon 11), 790 and 791 (exon 13), and V804L (exon 14) and 891 (exon 15).

Germline mutations in FMTC kindreds are more equally distributed throughout the *RET* gene and include mutations at codons 532, 533 (exon 8), 609, 611, 618, 620 (exon 10), 630, 634 (exon 11), 768, 790, 791 (exon 13), V804M, 844 (exon 14), 891 (exon 15), and 912 (exon 16) (10,107). Mutations at codons 532, 533, 768, 844, and 912 have been identified only in families with FMTC (17,107,108). Although mutations at codon 804 were initially believed to be associated with FMTC, subsequent analysis identified patients with pheochromocytoma harboring this mutation (109–112). Presently, the V804M mutation has been associated only with FMTC, whereas pheochromocytoma has been reported in a family with the V804L mutation (110).

A single point mutation at codon 918 (intracellular domain, exon 16) is present in most patients with MEN 2B (95%). A few patients with MEN 2B may also have a mutation in codon 883 (intracellular tyrosine kinase domain, exon 15) (10,95,113–115). Several authors have previously described codon 922 in association with MEN 2B; however, these reports included patients with either somatic codon 922 mutations present only within tumor cells or a compound heterozygous genotype with germline codon 918 and 922 mutations (84,116–118). Kitamura et al. (118) found that the codon 922 mutation, which was maternally inherited (the codon 918 mutation occurred de novo in the patient), did not cause features of MEN 2B in the patient's mother and, therefore, concluded that the codon 922 mutation is unlikely to seriously affect the function of RET and seems not to confer a deleterious effect. Additional *RET* mutations associated with MEN 2B include compound heterozygous mutations of V804M with Y806C and V804M with S904C (119,120).

No association has been found between mutations at codons 918 or 883 and HPT (9). Pheochromocytomas are most frequently associated with mutations in codons 634 and 918, but all MEN 2-associated mutations with the possible exception of the codon 791 mutation have been associated with pheochromocytoma (9,121).

Recently it was suggested that the biologic aggressiveness of MTC is associated with the specific *RET* mutation (101). *RET* mutations have been stratified into three groups (levels 1 to 3) based on the biologic aggressiveness of MTC observed in patients with these mutations (Fig. 2, Table 2). Patients with level 1 mutations (codons 609, 768, 790, 791, 804, and 891) have a high risk for the development and growth of MTC. Initial clinical observations suggested that mutations at codons 768 and 804 may have low penetrance and, in particular, that patients with codon 804 mutations may develop MTC at an older age. However, subsequently it was found that the age at onset and the aggressiveness of MTC in association with this mutation may vary (112,122). For example, in Frohnauer and colleagues' (122) report of affected individuals within families with a codon 804 mutation, one patient with a V804M mutation was diagnosed with MTC and distant metastases at age 6 years and ultimately died at age 12 years, whereas another patient from a separate family with a V804M mutation was found to have normal thyroid histology following prophylactic thyroidectomy at age 27 years (122). Patients with level 2 mutations (codons 611, 618, 620, and 634) have a higher risk for the early development and growth of MTC, and invasive MTC may be present as early as 5 years (9). However, there have been two reports of younger patients—a 15-month-old and a 17-

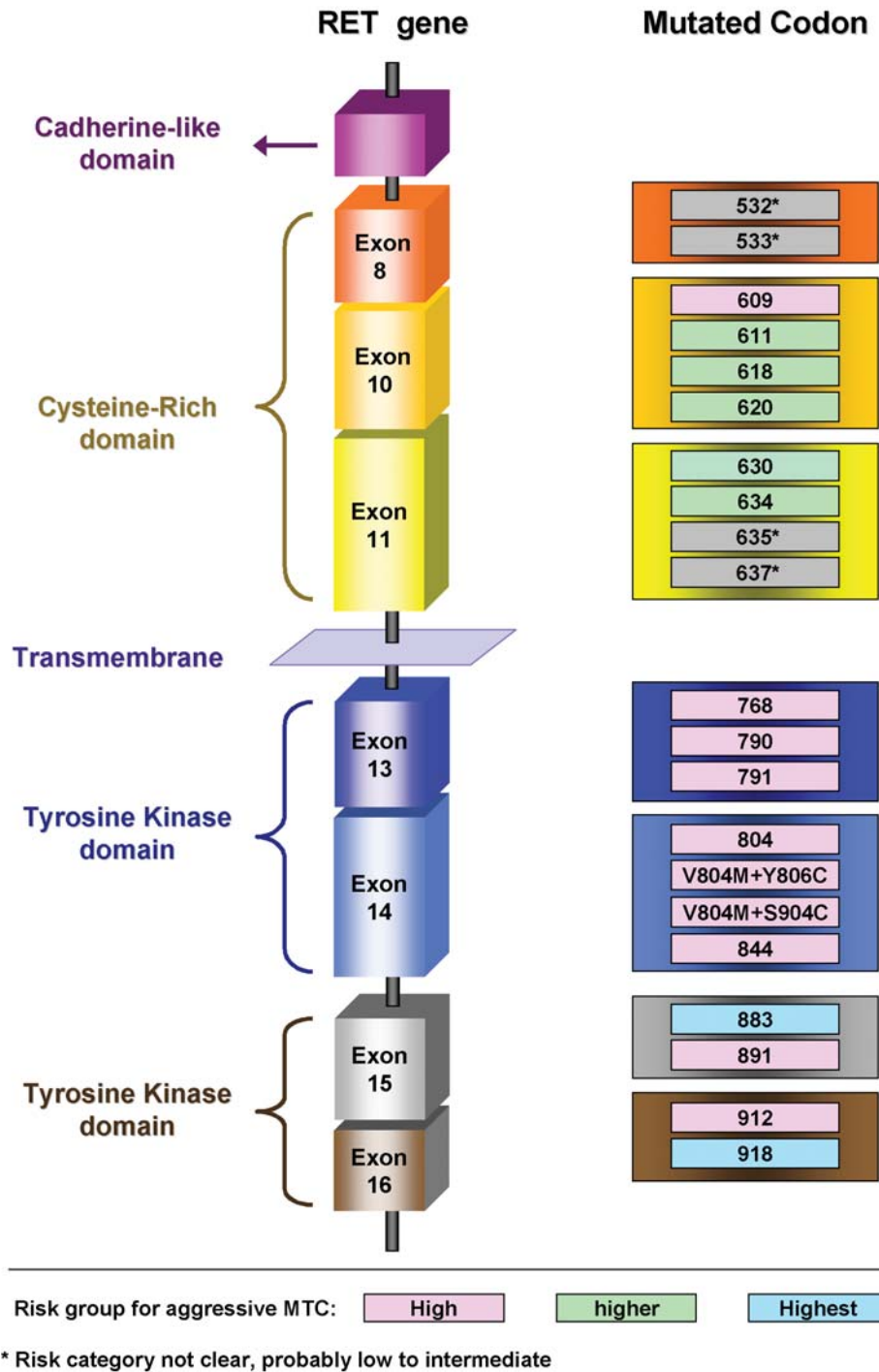


FIG. 2. Schematic diagram of the RET gene and reported codons responsible for the three levels of biologic aggressiveness of medullary thyroid carcinoma (MTC).

month-old—with a codon 634 mutation in whom focal MTC was found in the thyroid specimen following prophylactic thyroidectomy (29,123). Finally, patients with level 3 mutations (codons 883 and 918) have the highest risk for the early development and growth of MTC (9).

A recent review of the patients with hereditary MTC treated at our institution included 86 patients from 47 kindreds with FMTC or MEN 2; 83% of these patients underwent complete RET mutation analysis (101). The majority of the mutations

were in codons 609, 611, 618, 620, and 634, with the last of these representing the most frequent mutation. Level 3 RET mutations all involved codon 918. All types of level 2 RET mutations (codons 611, 618, 620, and 634) were represented in our population. Level 1 RET mutations involved codons 609, 804, and 891. Of the kindreds with level 1 mutations, 11% had MEN 2A, 33% had FMTC, and 56% were unclassified. Of the kindreds with level 2 mutations, 68% had MEN 2A, 14% had FMTC, and 18% were unclassified. All patients with level 3

TABLE 2. PATIENT RISK GROUPS AND ASSOCIATED MEDULLARY THYROID CARCINOMA CHARACTERISTICS

	High risk, level 1	Higher risk, level 2	Highest risk, level 3
Mutated codon	609, 768, 790, 791, 804, 891	611, 618, 620, 634	883, 918
Clinical subtype (% within risk level) <sup>a</sup>	MEN 2A (11%), FMTC (33%), Unclassified (56%)	MEN 2A (68%), FMTC (14%), Unclassified (18%)	MEN 2B (100%)

<sup>a</sup>Data from Brandi et al. (9) and Yip et al. (101).

FMTC, familial medullary thyroid carcinoma; HPT, hyperparathyroidism; MEN, multiple endocrine neoplasia; MTC, medullary thyroid carcinoma.

mutations had MEN 2B. Univariate and multivariate logistic regression analysis was used to explore the association of age at thyroidectomy and risk group (levels 1 to 3) with the aggressiveness (stage) of MTC at diagnosis. On the basis of the univariate analysis, older age at thyroidectomy was significantly associated with the likelihood of having stage III or IV MTC (American Joint Committee on Cancer staging system, 6th edition) (124) (odds ratio [OR], 1.06 per year of age at thyroidectomy; 95% confidence interval [CI], 1.02–1.10;  $p = 0.004$ ). In addition, the likelihood of having stage III or IV MTC at the time of diagnosis increased threefold for each increase in the MTC risk group from level 1 to level 3 (95% CI, 1.01–9.28;  $p < 0.001$ ). On multivariate analysis, the relationship of advanced MTC (stage III or IV) at the time of diagnosis to age at thyroidectomy and risk group became more pronounced. The risk of having stage III or IV MTC at the time of diagnosis increased 12% per year of age at thyroidectomy (95% CI, 1.07–1.17;  $p < 0.001$ ) and increased 14-fold for each incremental increase in the MTC risk group from level 1 to level 3 (95% CI, 3.05–66.55;  $p < 0.001$ ). This study confirmed that the biologic behavior of MTC can be stratified by the specific *RET* mutations in a MEN 2 population. Because age is an independent predictor of aggressive disease at thyroidectomy, early thyroidectomy in at-risk patients with level 2 and 3 mutations can potentially reduce the risk of MTC to that for patients with lower risk mutations. Such data support the practice of early thyroidectomy in higher risk patients.

In our series, pheochromocytomas were diagnosed in 24% of the patients, and the majority (76%) of patients with these tumors had mutations in codon 634 (101). Pheochromocytomas were bilateral at initial presentation in 52%. Of the patients who had unilateral pheochromocytoma at the time of initial diagnosis, 30% developed a contralateral pheochromocytoma at a median of 2.6 years after initial adrenalectomy.

HPT developed in 12% of our MEN 2 patients, the majority of whom (70%) had mutations in codon 634. CLA was found in 12% of our MEN 2 patients, and all affected patients had mutations in codon 634. One of our patients with a C620R mutation had manifestations of the clinical variant MEN 2A/HSCR. As expected, none of our patients with codon 918 mutations were diagnosed with HPT.

### Relationship of MEN 2 and HSCR

HSCR, or colonic aganglionosis, occurs in 1 in 5000 births and is characterized by the absence of enteric ganglia affecting various lengths of the colon (125). Two clinical types

of HSCR have been described: Short-segment HSCR, which involves the rectum and a small portion of the colon, accounts for approximately 80% of cases; and long-segment HSCR, which involves a larger portion of the intestine, makes up the remaining 20% of cases. Familial incidence appears to be higher for long-segment HSCR, and interestingly, trends of male predominance and a maternal parent-of-origin have been described (125–128).

HSCR can occur as isolated (nonsyndromic) cases or as part of another genetic syndrome, such as MEN 2. The underlying molecular mechanisms causing both isolated and syndromic cases of HSCR are likely multifactorial as well as multigenic (129,130). For example, at least eight susceptibility genes have been reported to be associated with HSCR, but the most common gene responsible for both isolated and syndromic cases of HSCR is *RET* (131). Inactivating mutations throughout the intracellular and extracellular regions of *RET* account for up to 50% of familial and approximately 35% of sporadic cases of HSCR (74–76).

It is perplexing how activating mutations in *RET* in the extracellular cysteine-rich residues of codons 609, 611, 618, and 620 allow HSCR to cosegregate in as many as 16% of kindreds with MEN 2A (18,132). One theory to explain this finding is that a single activating germline *RET* mutation is sufficient to cause both HSCR and MTC in these kindreds (68). However, evidence strongly suggests that the presence of *RET* haplotypes containing polymorphisms can cause or modify the HSCR phenotype (126,133–135). For instance, Borrego et al. (133,134) described a kindred with coexpression of MEN 2A and HSCR caused by a codon 620 mutation. The only living member of the kindred expressing both MEN 2A and HSCR carried both the codon 620 mutation and a silent c135G/A mutation in exon 2 (i.e., A45A) in a homozygous state, suggesting that this haplotype is required for expression of both MEN 2 and HSCR within this kindred. To date, several polymorphisms within the coding sequence and intronic splice sites of *RET* have been documented to support the theory that specific *RET* haplotypes are sufficient to cause or modify the HSCR phenotype (126,133,135).

### Genetic Testing for Hereditary MTC

Until 1987, the only available test to detect MTC in at-risk individuals was measurement of plasma levels of CT, the primary secretory product of MTC (136,137). Abnormal plasma CT levels after stimulation with pentagastrin were used to identify patients with hereditary MTC or C-cell hy-

perplasia, thereby allowing surgery to be performed at a relatively early age (138–140). Since then, DNA-based diagnosis of MEN 2 has replaced measurement of stimulated CT levels in the identification of *RET* mutation carriers (16). Detection of *RET* mutation carriers in kindreds with hereditary MTC allows for early intervention with prophylactic thyroidectomy and may alter the course of MTC, reducing both disease-related morbidity and death. In addition, up to 6% of patients with apparently sporadic MTC have been found to carry germline *RET* mutations (17,141). This is especially likely in patients who are diagnosed with MTC at a young age or who have multifocal disease despite the absence of a family history of hereditary MTC. Correct diagnosis of these patients is essential for the identification of additional affected family members. Therefore, it has been suggested that all patients with apparently sporadic MTC be tested for *RET* mutations (9). Such *RET* testing is recommended by the American Society of Clinical Oncology, the National Comprehensive Cancer Network, and the International MEN99 workshop (9,142).

Techniques to detect *RET* mutations include DNA-poly-morphism analysis (143), single-stranded conformational polymorphism analysis, restriction enzyme analysis, denaturing gradient gel electrophoresis, heteroduplex analysis, allele-specific oligonucleotide hybridization, and DNA sequencing. DNA sequencing for common mutations by amplification of selected exons (usually exons 10, 11, 13, 14, 15, and 16) known to be mutated in patients with MEN 2 (as is usually performed in most commercial laboratories) and DNA sequencing of all exons are considered the most accurate techniques because these methods can identify new, unreported mutations. Genetic counseling is essential for patients and their families who face the risk of hereditary MTC, for both educational and therapeutic reasons. Genetic counseling helps patients understand the medical facts of this disorder and how heredity influences the risk of disease in other relatives (144).

### Clinical Management of MTC Based on Genotype

The optimal treatment strategy is to prevent hereditary MTC by performing early thyroidectomy before malignant transformation occurs. However, if MTC is already present, complete surgical resection will maximize local disease control and survival duration (145). The adequacy of the initial operation is the most important determinant of outcome (145–147). The timing of surgical intervention in patients being evaluated for prophylactic thyroidectomy and the extent of surgery in patients with established MTC are based on the specific *RET* mutation risk group. The international MEN99 workshop agreed that prophylactic thyroidectomy should be reserved for patients who carry a *RET* mutation and that the timing of thyroidectomy should be based on the *RET* mutation risk level (9). When thyroidectomy is performed for prevention, a total extracapsular thyroidectomy is indicated. Whether prophylactic central neck dissection should be performed depends on the patient's mutation risk group, plasma CT level, and findings on preoperative ultrasonography.

Patients with level 1 mutations are often older at presentation and have more indolent tumors than do patients with level 2 or 3 mutations. For example, we previously reported a patient with a V804M (level 1) mutation who presented at

age 55 years with a palpable thyroid mass. After thyroidectomy and central and bilateral neck dissection, the patient was found to have multifocal, bilateral MTC but no evidence of metastases in the 60 lymph nodes examined. Postoperative CT levels in this patient fell to less than 1 pg/mL. In contrast, a patient with an M918T (level 3) mutation presented at age 17 years with mucosal neuromas, which are characteristic of MEN 2B, and was found to have invasive MTC already. Pathologic analysis of the thyroidectomy and neck dissection specimen demonstrated multifocal MTC with bilateral metastases in 32 of 71 lymph nodes; this patient developed bone and liver metastases within 5 years. Because patients with level 1 mutations develop MTC with less aggressive metastatic potential and also have an initial delay in the neoplastic transformation of the thyroid C cells; there is no consensus on the timing of thyroidectomy in these patients; some experts recommend prophylactic thyroidectomy by age 5 years, whereas others suggest that surgery can safely be delayed until age 10 years (9). Alternatively, one may obtain periodic basal and stimulated CT levels in these patients and perform total thyroidectomy at the first sign of an abnormal test result (142). However, serum CT levels cannot differentiate between C-cell hyperplasia and invasive MTC (145). If thyroidectomy is delayed, patients with level 1 mutations may develop lymph node and distant metastases. One of our patients with an S891A mutation presented with bone metastases at age 29 years and within 6 years had developed metastases in the liver, lung, and breast. Although unusual for a carrier of a level 1 mutation, this case emphasizes the heterogeneity in biologic behavior, which may complicate the management of patients who postpone thyroidectomy.

Patients with level 2 and 3 mutations have a higher risk for the early development and growth of MTC. Thus, early prophylactic thyroidectomy in at-risk individuals with these mutations may reduce the risk of MTC to that for patients with lower risk mutations. Current guidelines for the treatment of patients with level 2 mutations include total thyroidectomy by the age of 5 years (9). However, invasive MTC can be found in young patients with level 2 mutations who have undergone prophylactic thyroidectomy. One of our patients with a C634R mutation had undergone prophylactic thyroidectomy at age 5 years and was found to have a 4-mm focus of MTC in the right thyroid lobe. Because of our anecdotal experience with this patient as well as the inability of serum CT levels to differentiate between C-cell hyperplasia and invasive MTC, we currently prefer to perform prophylactic thyroidectomy before the age of 5 years in patients with level 2 *RET* mutations (145). Although lymph node metastases have been reported in a 5-year-old child with a level 2 mutation, prophylactic central neck dissection for these patients is rarely performed (9,148). We do not add regional lymphadenectomy (central or lateral neck) to a prophylactic thyroidectomy unless findings from ultrasonography, basal CT levels, and/or patient age raise suspicion for the presence of occult lymph node metastases.

Patients with level 3 mutations have the highest risk for developing aggressive MTC, and prophylactic total thyroidectomy should be performed by the age of 6 months or preferably within the first month of life (9). In patients who are diagnosed later in childhood, regional lymph node metastases are usually present and require dissection of the

central (level VI) and both lateral (levels IIa, III, IV, and V) compartments.

### Clinical Management of Hereditary Pheochromocytoma

Routine biochemical screening for pheochromocytoma should be performed in all patients with MEN 2. In FMTC kindreds, periodic screening for pheochromocytoma may be warranted as some FMTC families—particularly those that are small, have vague or limited histories, or have a predominance of young individuals—may manifest disease over time that suggests a phenotype more consistent with MEN 2A. We currently screen all at-risk patients yearly with measurements of either plasma or 24-hour urinary fractionated metanephrines. The risk for pheochromocytoma is reportedly high in MEN 2A patients with codon 634 mutations. Moreover, pheochromocytoma has been identified as early as 5 years in carriers with this mutation (9). Thus, biochemical screening should be considered by the age of 5 to 7 years in these patients (9).

Pheochromocytomas in patients with MEN 2 appear to be biologically distinct from sporadic tumors in that the former are rarely extra-adrenal or malignant and are diagnosed at a younger age. The absence of metastatic pheochromocytoma in patients with hereditary pheochromocytoma and the risk of morbidity and death from adrenal insufficiency in MEN 2 patients who undergo bilateral total adrenalectomy support the surgical practice of cortex-sparing adrenalectomy. Prophylactic adrenalectomy is not recommended.

In a recent report from our institution, we identified 59 patients from 40 kindreds who underwent surgical resection for hereditary pheochromocytoma or paraganglioma (149). Thirty-nine patients were diagnosed with MEN 2A, 7 with MEN 2B, 6 with von Hippel-Lindau disease, 3 with neurofibromatosis type 1, and 2 each with MEN type 1 and familial paraganglioma syndrome. Pheochromocytoma or paraganglioma was the initial manifestation of a hereditary syndrome in 9 (15%) of 59 patients, including 6 patients (15%) with MEN 2A, 1 (17%) with von Hippel-Lindau disease, and both patients with familial paraganglioma syndrome. Pheochromocytomas were present in 56 (95%) of 59 patients. At the first adrenal operation, pheochromocytomas were pathologically confirmed to be bilateral in 27 (48%) of 56 patients and unilateral in 29 (52%); malignant pheochromocytoma was not present in any patients. Detailed pedigree analysis of the 39 kindreds with MEN 2A, MEN 2B, von Hippel-Lindau disease, MEN 1, or neurofibromatosis type 1 revealed a history suggesting malignant pheochromocytoma in a single patient from a kindred with MEN 2A based upon an isolated entry in the medical record; however, histopathologic confirmation was not available.

Unilateral adrenalectomy was performed in 25 (45%) of 56 patients, and 7 (28%) developed recurrent pheochromocytoma in the contralateral adrenal gland (149). In total, 38 patients were at risk for adrenal insufficiency as a result of having undergone bilateral adrenal procedures either concurrently for synchronous disease or separately after the development of recurrent contralateral pheochromocytoma. Signs and symptoms of acute adrenal insufficiency (Addisonian crisis) occurred in 4 (11%) of 38 patients after their last adrenal operation. Three of these 4 patients had undergone bilateral

total adrenalectomy. In total, 26 patients underwent cortical-sparing adrenalectomy as part of bilateral adrenalectomy; 17 (65%) were corticosteroid independent either at last follow-up or prior to completion total adrenalectomy. The risk of recurrent pheochromocytoma in the remnant adrenal gland treated with the cortical-sparing technique was 10%.

Our experience suggests that metastatic pheochromocytoma rarely occurs in patients with hereditary pheochromocytoma (0/56 patients), cortical-sparing adrenalectomy prevents the need for chronic corticosteroid replacement in the majority (65%) of patients, and the risk of recurrent pheochromocytoma in the remnant adrenal gland after cortical-sparing adrenalectomy is low (10%). We therefore have adopted the following surgical strategy for hereditary pheochromocytoma. In patients with a unilateral pheochromocytoma and a normal contralateral gland, our preferred procedure is a laparoscopic, unilateral total adrenalectomy. In patients who present with bilateral pheochromocytomas, we use a midline incision to perform a unilateral cortical-sparing procedure with removal of the entire contralateral gland. In general, we prefer to preserve the cortex on only one side rather than assume double the risk of recurrent pheochromocytoma by preserving the cortex on both sides. Finally, in patients who present with a metachronous contralateral pheochromocytoma following a previous unilateral total adrenalectomy, we prefer an open cortical-sparing procedure. Short-term follow-up in all patients includes reinforcement of preoperative patient education about adrenal insufficiency and regularly scheduled testing of adrenal reserve. Long-term follow-up includes monitoring of the remaining adrenal gland or portion of adrenal gland for recurrent pheochromocytoma with yearly plasma or urinary screening studies.

### Conclusion

The biologic behavior of MTC can be stratified by the specific *RET* mutation in patients with hereditary MTC. DNA-based mutation analysis of the *RET* proto-oncogene in at-risk patients is important for the detection of gene carriers and the identification of the specific mutation. Both older age at thyroidectomy and MTC risk group are independent predictors of MTC aggressiveness. Because of the importance of early intervention in the management of MTC and of screening for pheochromocytoma, the identification of *RET* mutation carriers can minimize disease-related morbidity and deaths. The comprehensive care of patients with MEN 2 or FMTC should also include appropriate genetic counseling and long-term surveillance.

### Acknowledgment

M.A.K. is a recipient of an Odyssey Special Fellowship from The University of Texas M. D. Anderson Cancer Center.

### References

1. Hazard JB, Hawk WA, Crile G, Jr 1959 Medullary (solid) carcinoma of the thyroid; a clinicopathologic entity. *J Clin Endocrinol Metab* **19**:152–161.
2. Jemal A, Tiwari RC, Murray T, Ghafoor A, Samuels A, Ward E, Feuer EJ, Thun MJ, American Cancer Society 2004 Cancer Statistics, 2004. *CA Cancer J Clin* **54**:8–29.

3. Kebebew E, Ituarte PH, Siperstein AE, Duh QY, Clark OH 2000 Medullary thyroid carcinoma: Clinical characteristics, treatment, prognostic factors, and a comparison of staging systems. *Cancer* **88**:1139-1148.
4. Gilliland FD, Hunt WC, Morris DM, Key CR 1997 Prognostic factors for thyroid carcinoma. A population-based study of 15,698 cases from the Surveillance, Epidemiology and End Results (SEER) program 1973-1991. *Cancer* **79**:564-573.
5. Block MA, Jackson CE, Greenawald KA, Yott JB, Tashjian AH, Jr 1980 Clinical characteristics distinguishing hereditary from sporadic medullary thyroid carcinoma. Treatment implications. *Arch Surg* **115**:142-148.
6. Mulligan LM, Kwok JB, Healey CS, Elsdon MJ, Eng C, Gardner E, Love DR, Mole SE, Moore JK, Papi L, et al 1993 Germ-line mutations of the RET proto-oncogene in multiple endocrine neoplasia type 2A. *Nature* **363**:458-460.
7. Donis-Keller H, Dou S, Chi D, Carlson KM, Toshima K, Lairmore TG, Howe JR, Moley JF, Goodfellow P, Wells SA Jr 1993 Mutations in the RET proto-oncogene are associated with MEN 2A and FMTC. *Hum Mol Genet* **2**:851-856.
8. Online Mendelian Inheritance in Man, OMIM (TM). Johns Hopkins University, Baltimore, MD. MIM Number: #171400: Date last edited: September 11, 2003. www.ncbi.nlm.nih.gov/omim (Last accessed April 15, 2005).
9. Brandi ML, Gagel RF, Angeli A, Bilezikian JP, Beck-Peccoz P, Bordi C, Conte-Devolx B, Falchetti A, Gheri RG, Libroia A, Lips CJ, Lombardi G, Mannelli M, Pacini F, Ponder BA, Raue F, Skoaseia B, Tamburrano G, Thakker RV, Thompson NW, Tomassitti P, Tonelli F, Wells SA Jr, Marx SJ 2001 Guidelines for diagnosis and therapy of MEN type 1 and type 2. *J Clin Endocrinol Metab* **86**:5658-5671.
10. Eng C, Clayton D, Schuffenecker I, Lenoir G, Cote G, Gagel RF, van Amstel HK, Lips CJ, Nishisho I, Takai SI, Marsh DJ, Robinson BG, Frank-Ranek, Raue F, Xue F, Noll WW, Romei C, Pacini F, Fink M, Niederle B, Zederius J, Nordenskjold M, Komminoth P, Hendy GN, Mulligan LM, et al 1996 The relationship between specific RET proto-oncogene mutations and disease phenotype in multiple endocrine neoplasia type 2. International RET mutation consortium analysis. *Jama* **276**:1575-1579.
11. Sipple J 1961 The association of pheochromocytoma with carcinomas of the thyroid gland. *Am J Med* **31**:163-166.
12. Steiner AL, Goodman AD, Powers SR 1968 Study of a kindred with pheochromocytoma, medullary thyroid carcinoma, hyperparathyroidism and Cushing's disease: Multiple endocrine neoplasia, type 2. *Medicine (Baltimore)* **47**:371-409.
13. Ponder BA, Ponder MA, Coffey R, Pembrey ME, Gagel RF, Telenius-Berg M, Semple P, Easton DP 1988 Risk estimation and screening in families of patients with medullary thyroid carcinoma. *Lancet* **1**:397-401.
14. Easton DF, Ponder MA, Cummings T, Gagel RF, Hansen HH, Ruchlin S, Tashjian AH Jr, Telenius-Berg M, Ponder BA 1989 The clinical and screening age-at-onset distribution for the MEN-2 syndrome. *Am J Hum Genet* **44**:208-215.
15. Landsvater RM, Rombouts AG, te Meerman GJ, Schilhorn-van Veen JM, Berends MJ, Geerdink RA, Struyorenberg A, Buys CH, Lips CJ 1993 The clinical implications of a positive calcitonin test for C-cell hyperplasia in genetically unaffected members of an MEN2A kindred. *Am J Hum Genet* **52**:335-342.
16. Lips CJ, Landsvater RM, Hoppener JW, Geerdink RA, Blijham G, van Veen JM, van Gils AP, de Wit MJ, Zewald RA, Berends MJ, et al 1994 Clinical screening as compared with DNA analysis in families with multiple endocrine neoplasia type 2A. *N Engl J Med* **331**:828-835.
17. Eng C, Mulligan LM, Smith DP, Healey CS, Frilling A, Raue F, Neumann HP, Ponder MA, Ponder BA 1995 Low frequency of germline mutations in the RET proto-oncogene in patients with apparently sporadic medullary thyroid carcinoma. *Clin Endocrinol (Oxf)* **43**:123-127.
18. Decker RA, Peacock ML, Watson P 1998 Hirschsprung disease in MEN 2A: Increased spectrum of RET exon 10 genotypes and strong genotype-phenotype correlation. *Hum Mol Genet* **7**:129-134.
19. Gagel RF, Levy ML, Donovan DT, Alford BR, Wheeler T, Tschen JA 1989 Multiple endocrine neoplasia type 2a associated with cutaneous lichen amyloidosis. *Ann Intern Med* **111**:802-806.
20. Gorlin RJ, Sedano HO, Vickers RA, Cervenka J 1968 Multiple mucosal neuromas, pheochromocytoma and medullary carcinoma of the thyroid—A syndrome. *Cancer* **22**:293-299 passim.
21. Koch CA, Pacak K, Chrousos GP 2002 The molecular pathogenesis of hereditary and sporadic adrenocortical and adrenomedullary tumors. *J Clin Endocrinol Metab* **87**:5367-5384.
22. Webb TA, Sheps SG, Carney JA 1980 Differences between sporadic pheochromocytoma and pheochromocytoma in multiple endocrine neoplasia, type 2. *Am J Surg Pathol* **4**:121-126.
23. Inabnet WB, Caragliano P, Pertsemlidis D 2000 Pheochromocytoma: inherited associations, bilaterality, and cortex preservation. *Surgery* **128**:1007-1011;discussion 1011-1002.
24. Neumann HP, Bausch B, McWhinney SR, Bender BU, Gimm O, Franke G, Schipper J, Klisch J, Althoefer C, Zerres K, Januszewicz A, Eng C, Smith WM, Munk R, Manz T, Glaesker S, Apel TW, Treier M, Reineke M, Walz MK, Hoang-Vu C, Brauckhoff M, Klein-Franke A, Klose P, Schmidt H, Maier-Woelfle M, Peczkowska M, Szmigielski C, Eng C, Freiburg-Warsaw-Columbus Pheochromocytoma Study Group 2002 Germ-line mutations in nonsyndromic pheochromocytoma. *N Engl J Med* **346**:1459-1466.
25. Conte-Devolx B, Schuffenecker I, Niccoli P, Maes B, Boneu A, Barbot M, Corcuff JB, Murat A, Henry JF, Modigliani E 1997 Multiple endocrine neoplasia type 2: Management of patients and subjects at risk. French Study Group on Calcitonin-Secreting Tumors (GETC). *Horm Res* **47**:221-226.
26. Modigliani E, Vasen HM, Raue K, Dralle H, Frilling A, Gheri RG, Brandi ML, Limbert E, Niederle B, Forgas L, et al 1995 Pheochromocytoma in multiple endocrine neoplasia type 2: European study. The Euromen Study Group. *J Intern Med* **238**:363-367.
27. Eng C 1999 RET proto-oncogene in the development of human cancer. *J Clin Oncol* **17**:380-393.
28. Farndon JR, Leight GS, Dilley WG, Baylin SB, Smallridge RC, Harrison TS, Wells SA Jr 1986 Familial medullary thyroid carcinoma without associated endocrinopathies: A distinct clinical entity. *Br J Surg* **73**:278-281.
29. Sanso GE, Domene HM, Garcia R, Pusiol E, de M Rogue M, Ring A, Perinetti H, Elsner B, Iorcansky S, Barontini M 2002 Very early detection of RET proto-oncogene mutation is crucial for preventive thyroidectomy in multiple endocrine neoplasia type 2 children: Presence of C-cell malignant disease in asymptomatic carriers. *Cancer* **94**:323-330.
30. Kaufman FR, Roe TF, Isaacs H, Jr, Weitzman JJ 1982 Metastatic medullary thyroid carcinoma in young children with mucosal neuroma syndrome. *Pediatrics* **70**:263-267.

31. Wohllk N, Cote GJ, Evans DB, Goepfert H, Ordonez NG, Gagel RF 1996 Application of genetic screening information to the management of medullary thyroid carcinoma and multiple endocrine neoplasia type 2. *Endocrinol Metab Clin North Am* **25**:1–25.
32. Takahashi M, Ritz J, Cooper GM 1985 Activation of a novel human transforming gene, *ret*, by DNA rearrangement. *Cell* **42**:581–588.
33. Takahashi M, Buma Y, Iwamoto T, Inaguma Y, Ikeda H, Hiai H 1988 Cloning and expression of the *ret* proto-oncogene encoding a tyrosine kinase with two potential transmembrane domains. *Oncogene* **3**:571–578.
34. Pachnis V, Mankoo B, Costantini F 1993 Expression of the *c-ret* proto-oncogene during mouse embryogenesis. *Development* **119**:1005–1017.
35. Tsuzuki T, Takahashi M, Asai N, Iwashita T, Matsuyama M, Asai J 1995 Spatial and temporal expression of the *ret* proto-oncogene product in embryonic, infant and adult rat tissues. *Oncogene* **10**:191–198.
36. Tahira T, Ishizaka Y, Itoh F, Sugimura T, Nagao M 1990 Characterization of *ret* proto-oncogene mRNAs encoding two isoforms of the protein product in a human neuroblastoma cell line. *Oncogene* **5**:97–102.
37. Myers SM, Eng C, Ponder BA, Mulligan LM 1995 Characterization of *RET* proto-oncogene 3' splicing variants and polyadenylation sites: A novel C-terminus for *RET*. *Oncogene* **11**:2039–2045.
38. Takahashi M 2001 The GDNF/*RET* signaling pathway and human diseases. *Cytokine Growth Factor Rev* **12**:361–373.
39. de Graaff E, Srinivas S, Kilkenny C, D'Agati V, Mankou BS, Constantini F, Pachnis V 2001 Differential activities of the *RET* tyrosine kinase receptor isoforms during mammalian embryogenesis. *Genes Dev* **15**:2433–2444.
40. Lee DC, Chan KW, Chan SY 2002 *RET* receptor tyrosine kinase isoforms in kidney function and disease. *Oncogene* **21**:5582–5592.
41. Tsui-Pierchala BA, Milbrandt J, Johnson EM, Jr 2002 NGF utilizes *c-Ret* via a novel GFL-independent, inter-RTK signaling mechanism to maintain the trophic status of mature sympathetic neurons. *Neuron* **33**:261–273.
42. Tsui-Pierchala BA, Ahrens RC, Crowder RJ, Milbrandt J, Johnson EM, Jr 2002 The long and short isoforms of *Ret* function as independent signaling complexes. *J Biol Chem* **277**:34618–34625.
43. Jing S, Wen D, Yu Y, Holst PL, Luo Y, Fang M, Tamir R, Antonio L, Hu Z, Cupples R, Louis JC, Hu S, Altrock BW, Fox GM 1996 GDNF-induced activation of the *ret* protein tyrosine kinase is mediated by GDNFR- $\alpha$ , a novel receptor for GDNF. *Cell* **85**:1113–1124.
44. Treanor JJ, Goodman L, de Sauvage F, Stone DM, Poulsen KT, Beck CD, Gray C, Armanini MP, Pollock RA, Hefti F, Phillips HS, Goddard A, Moore MW, Buj-Bello A, Davies AM, Asai N, Takahashi M, Vandlen R, Henderson CE, Rosenthal A 1996 Characterization of a multicomponent receptor for GDNF. *Nature* **382**:80–83.
45. Baloh RH, Tansey MG, Lampe PA, Fahrner TJ, Enomoto H, Simburger KS, Leitner ML, Araki T, Johnson EM Jr, Milbrandt J 1998 *Artemin*, a novel member of the GDNF ligand family, supports peripheral and central neurons and signals through the GFR $\alpha$ 3–*RET* receptor complex. *Neuron* **21**:1291–1302.
46. Airaksinen MS, Titievsky A, Saarma M 1999 GDNF family neurotrophic factor signaling: Four masters, one servant? *Mol Cell Neurosci* **13**:313–325.
47. Milbrandt J, de Sauvage FJ, Fahrner TJ, Milbrandt J, de Sauvage FJ, Fahrner TJ, Baloh RH, Leitner ML, Tansey MG, Lampe PA, Heuckeroth RO, Kotzbauer PT, Simburger KS, Golden JP, Davies JA, Vejsada R, Kato AC, Hynes M, Sherman D, Nishimura M, Wang LC, Vandlen R, Moffat B, Klein RD, Poulsen K, Gray C, Garces A, Johnson Em Jr, et al 1998 *Persephin*, a novel neurotrophic factor related to GDNF and *neurturin*. *Neuron* **20**:245–253.
48. Kotzbauer PT, Lampe PA, Heuckeroth RO, Golden JP, Creedon DJ, Johnson EM, Jr, Milbrandt J 1996 *Neurturin*, a relative of glial-cell-line-derived neurotrophic factor. *Nature* **384**:467–470.
49. Baloh RH, Enomoto H, Johnson EM, Jr, Milbrandt J 2000 The GDNF family ligands and receptors—implications for neural development. *Curr Opin Neurobiol* **10**:103–110.
50. Sanicola M, Hession C, Worley D, Carmillo P, Ehrenfels C, Walus L, Robinson S, Jaworski G, Wei H, Tizard R, Whitty A, Pepinsky RB, Cate RL 1997 Glial cell line-derived neurotrophic factor-dependent *RET* activation can be mediated by two different cell-surface accessory proteins. *Proc Natl Acad Sci USA* **94**:6238–6243.
51. Creedon DJ, Tansey MG, Baloh RH, Osborne PA, Lampe PA, Fahrner TJ, Heuckeroth RO, Milbrandt J, Johnson EM Jr 1997 *Neurturin* shares receptors and signal transduction pathways with glial cell line-derived neurotrophic factor in sympathetic neurons. *Proc Natl Acad Sci USA* **94**:7018–7023.
52. Airaksinen MS, Saarma M 2002 The GDNF family: Signalling, biological functions and therapeutic value. *Nat Rev Neurosci* **3**:383–394.
53. Ohiwa M, Murakami H, Iwashita T, Asai N, Iwata Y, Imai T, Funahashi H, Takagi H, Takahashi M 1997 Characterization of *Ret*-Shc-Grb2 complex induced by GDNF, *MEN 2A*, and *MEN 2B* mutations. *Biochem Biophys Res Commun* **237**:747–751.
54. van Weering DH, Medema JP, van Puijenbroek A, Burgering BM, Baas PD, Bos JL 1995 *Ret* receptor tyrosine kinase activates extracellular signal-regulated kinase 2 in SK-N-MC cells. *Oncogene* **11**:2207–2214.
55. Worby CA, Vega QC, Zhao Y, Chao HH, Seasholtz AF, Dixon JE 1996 Glial cell line-derived neurotrophic factor signals through the *RET* receptor and activates mitogen-activated protein kinase. *J Biol Chem* **271**:23619–23622.
56. van Weering DH, Bos JL 1997 Glial cell line-derived neurotrophic factor induces *Ret*-mediated lamellipodia formation. *J Biol Chem* **272**:249–254.
57. Xing S, Furminger TL, Tong Q, Jhiang SM 1998 Signal transduction pathways activated by *RET* oncoproteins in PC12 pheochromocytoma cells. *J Biol Chem* **273**:4909–4914.
58. Chiariello M, Visconti R, Carlomagno F, Melillo RM, Bucci C, de Franciscis V, Fox GM, Jing S, Coso OA, Gutkind JS, Fusco A, Santoro M 1998 Signalling of the *Ret* receptor tyrosine kinase through the *c-Jun* NH2-terminal protein kinases (*JNKs*): Evidence for a divergence of the *ERKs* and *JNKs* pathways induced by *Ret*. *Oncogene* **16**:2435–2445.
59. Murakami H, Iwashita T, Asai N, Shimono Y, Iwata Y, Kawai K, Takahashi M 1999 Enhanced phosphatidylinositol 3-kinase activity and high phosphorylation state of its downstream signalling molecules mediated by *ret* with the *MEN 2B* mutation. *Biochem Biophys Res Commun* **262**:68–75.
60. Murakami H, Iwashita T, Asai N, Iwata Y, Narumiya S, Takahashi M 1999 Rho-dependent and -independent tyrosine phosphorylation of focal adhesion kinase,  *Paxillin*

- and p130Cas mediated by Ret kinase. *Oncogene* **18**: 1975–1982.
61. Melillo RM, Barone MV, Lupoli G, Cirafici AM, Carlomagno F, Visconti R, Matoskova B, Di Fiore PP, Vecchio G, Fusco A, Santoro M 1999 Ret-mediated mitogenesis requires Src kinase activity. *Cancer Res* **59**:1120–1126.
  62. Trupp M, Scott R, Whittmore SR, Ibanez CF 1999 Ret-dependent and -independent mechanisms of glial cell line-derived neurotrophic factor signaling in neuronal cells. *J Biol Chem* **274**:20885–20894.
  63. Soler RM, Dolcet X, Encinas M, Egea J, Bayascas JR, Comella JX 1999 Receptors of the glial cell line-derived neurotrophic factor family of neurotrophic factors signal cell survival through the phosphatidylinositol 3-kinase pathway in spinal cord motoneurons. *J Neurosci* **19**: 9160–9169.
  64. Feng L, Wang CY, Jiang H, Oho C, Dugich-Djordjevic M, Mei L, Lu B 1999 Differential signaling of glial cell line-derived neurotrophic factor and brain-derived neurotrophic factor in cultured ventral mesencephalic neurons. *Neuroscience* **93**:265–273.
  65. Hayashi H, Ichihara M, Iwashita T, Murakami H, Shimono Y, Kawai K, Kurokawa K, Murakumo Y, Imai T, Funahashi H, Nakao A, Takahashi M 2000 Characterization of intracellular signals via tyrosine 1062 in RET activated by glial cell line-derived neurotrophic factor. *Oncogene* **19**:4469–4475.
  66. Segouffin-Cariou C, Billaud M 2000 Transforming ability of MEN2A-RET requires activation of the phosphatidylinositol 3-kinase/AKT signaling pathway. *J Biol Chem* **275**:3568–3576.
  67. Ichihara M, Murakumo Y, Takahashi M 2004 RET and neuroendocrine tumors. *Cancer Lett* **204**:197–211.
  68. Takahashi M, Iwashita T, Santoro M, Lyonnet S, Lenoir GM, Billaud M 1999 Co-segregation of MEN2 and Hirschsprung's disease: The same mutation of RET with both gain and loss-of-function? *Hum Mutat* **13**:331–336.
  69. Donghi R, Sozzi G, Pierotti MA, Biunno I, Miozzo M, Fusco A, Grieco M, Santoro M, Vecchio G, Spurr NK, et al 1989 The oncogene associated with human papillary thyroid carcinoma (PTC) is assigned to chromosome 10 q11–q12 in the same region as multiple endocrine neoplasia type 2A (MEN2A). *Oncogene* **4**:521–523.
  70. Grieco M, Santoro M, Berlingieri MT, Melillo RM, Donghi R, Bongarzone I, Pierotti MA, Della Porta G, Fusco A, Vecchio G 1990 PTC is a novel rearranged form of the ret proto-oncogene and is frequently detected in vivo in human thyroid papillary carcinomas. *Cell* **60**:557–563.
  71. Edery P, Lyonnet S, Mulligan LM, Pelet A, Dow F, Abel L, Holder S, Nihoul-Fekete C, Ponder BA, Munnich A 1994 Mutations of the RET proto-oncogene in Hirschsprung's disease. *Nature* **367**:378–380.
  72. Romeo G, Ronchetto P, Luo Y, Barone V, Seri M, Ceccherini I, Pacini B, Bocciardi R, Lerone M, Kaarianen H, et al 1994 Point mutations affecting the tyrosine kinase domain of the RET proto-oncogene in Hirschsprung's disease. *Nature* **367**:377–378.
  73. Angrist M, Bolk S, Thiel B, Puffenberger EG, Hofstra RM, Buys CH, Cass DT, Chakravarti A 1995 Mutation analysis of the RET receptor tyrosine kinase in Hirschsprung disease. *Hum Mol Genet* **4**:821–830.
  74. Attie T, Pelet A, Edery P, Eng C, Mulligan LM, Amiel J, Boutrand L, Beldjord C, Nihoul-Fekete C, Munnich A, et al 1995 Diversity of RET proto-oncogene mutations in familial and sporadic Hirschsprung disease. *Hum Mol Genet* **4**:1381–1386.
  75. Eng C 1996 Seminars in medicine of the Beth Israel Hospital, Boston. The RET proto-oncogene in multiple endocrine neoplasia type 2 and Hirschsprung's disease. *N Engl J Med* **335**:943–951.
  76. Eng C, Mulligan LM 1997 Mutations of the RET proto-oncogene in the multiple endocrine neoplasia type 2 syndromes, related sporadic tumours, and hirschsprung disease. *Hum Mutat* **9**:97–109.
  77. Santoro M, Carlomagno F, Romano A, Bottaro DP, Dathan NA, Gricco M, Fusco A, Vecchio G, Matoskova B, Kraus MH, et al 1995 Activation of RET as a dominant transforming gene by germline mutations of MEN2A and MEN2B. *Science* **267**:381–383.
  78. Asai N, Iwashita T, Matsuyama M, Takahashi M 1995 Mechanism of activation of the ret proto-oncogene by multiple endocrine neoplasia 2A mutations. *Mol Cell Biol* **15**:1613–1619.
  79. Xing S, Smanik PA, Oglesbee MJ, Trosko JE, Mazzaferri EL, Jhiani SM 1996 Characterization of ret oncogenic activation in MEN2 inherited cancer syndromes. *Endocrinology* **137**:1512–1519.
  80. Akhand AA, Ikeyama T, Akazawa S, Kato M, Hossain K, Takeda K, Suzuki H, Takahashi M, Nakashima I 2002 Evidence of both extra- and intracellular cysteine targets of protein modification for activation of RET kinase. *Biochem Biophys Res Commun* **292**:826–831.
  81. Hofstra RM, Landsvater RM, Ceccherini I, Stulp RP, Stelwagen T, Luo Y, Pasini B, Hoppener JW, van Amstel HK, Romeo G, et al 1994 A mutation in the RET proto-oncogene associated with multiple endocrine neoplasia type 2B and sporadic medullary thyroid carcinoma. *Nature* **367**: 375–376.
  82. Eng C, Smith DP, Mulligan LM, Healey CS, Zvelebil MJ, Stonehouse TJ, Ponder MA, Jackson CE, Waterfield MD, Ponder BA 1995 A novel point mutation in the tyrosine kinase domain of the RET proto-oncogene in sporadic medullary thyroid carcinoma and in a family with FMTC. *Oncogene* **10**:509–513.
  83. Kalinin V, Frilling A 1998 27-bp deletion in the ret proto-oncogene as a somatic mutation associated with medullary thyroid carcinoma. *J Mol Med* **76**:365–367.
  84. Kalinin VN, Amosenko FA, Shabanov MA, Lubchenko LN, Hosch SB, Garkavtseva RF, Izbicki JR 2001 Three novel mutations in the RET proto-oncogene. *J Mol Med* **79**:609–612.
  85. Alemi M, Lucas SD, Sallstrom JF, Bergholm U, Akerstrom G, Wilander E 1997 A complex nine base pair deletion in RET exon 11 common in sporadic medullary thyroid carcinoma. *Oncogene* **14**:2041–2045.
  86. Chiefari E, Russo D, Giuffrida D, Zampa GA, Meringolo D, Arturi F, Chiodini I, Bianchi D, Attard M, Trischitta V, Bruno R, Giannasio P, Pontecorvi A, Filetti S 1998 Analysis of RET proto-oncogene abnormalities in patients with MEN 2A, MEN 2B, familial or sporadic medullary thyroid carcinoma. *J Endocrinol Invest* **21**:358–364.
  87. Eng C, Mulligan LM, Smith DP, Healey CS, Frilling A, Raue F, Neumann HP, Pfragner R, Behmel A, Lorenzo MJ, et al 1995 Mutation of the RET protooncogene in sporadic medullary thyroid carcinoma. *Genes Chromosomes Cancer* **12**:209–212.
  88. Marsh DJ, Learoyd DL, Andrew SD, Krishnan L, Pojer R, Richardson AL, Delbridge L, Eng C, Robinson BG 1996 Somatic mutations in the RET proto-oncogene in sporadic

- medullary thyroid carcinoma. *Clin Endocrinol (Oxf)* **44**: 249–257.
89. Scurini C, Quadro L, Fattoruso O, Verga U, Libroia A, Lupoli G, Cascone E, Marzano L, Paracchi S, Busnardo B, Girelli ME, Bellastella A, Colantuoni V 1998 Germline and somatic mutations of the RET proto-oncogene in apparently sporadic medullary thyroid carcinomas. *Mol Cell Endocrinol* **137**:51–57.
  90. Zedenius J, Larsson C, Bergholm U, Bovee J, Svensson A, Hallengren B, Grimelius L, Backdahl M, Weber G, Wallin G 1995 Mutations of codon 918 in the RET proto-oncogene correlate to poor prognosis in sporadic medullary thyroid carcinomas. *J Clin Endocrinol Metab* **80**:3088–3090.
  91. Beldjord C, Desclaux-Arramond F, Raffin-Sanson M, Corvol JC, De Keyzer Y, Lutton JP, Plouin PF, Bertagna X 1995 The RET protooncogene in sporadic pheochromocytomas: Frequent MEN 2–like mutations and new molecular defects. *J Clin Endocrinol Metab* **80**:2063–2068.
  92. Eng C, Crossey PA, Mulligan LM, Healey CS, Houghton C, Prowse A, Chew SL, Dahia PL, O’Riordan JL, Toledo SP, et al 1995 Mutations in the RET proto-oncogene and the von Hippel-Lindau disease tumour suppressor gene in sporadic and syndromic pheochromocytomas. *J Med Genet* **32**:934–937.
  93. Rodien P, Jeunemaitre X, Dumont C, Beldjord C, Plouin PF 1997 Genetic alterations of the RET proto-oncogene in familial and sporadic pheochromocytomas. *Horm Res* **47**: 263–268.
  94. Lindor NM, Honchel R, Khosla S, Thibodeau SN 1995 Mutations in the RET protooncogene in sporadic pheochromocytomas. *J Clin Endocrinol Metab* **80**:627–629.
  95. Eng C, Smith DP, Mulligan LM, Nagai MA, Healey CS, Ponder MA, Gardner E, Scheumann GF, Jackson CE, Tunnacliffe A, et al 1994 Point mutation within the tyrosine kinase domain of the RET proto-oncogene in multiple endocrine neoplasia type 2B and related sporadic tumours. *Hum Mol Genet* **3**:237–241.
  96. Elisei R, Cosci B, Romei C, Agate L, Piamplani P, Miccoli P, Berti P, Basolo F, Ugolini C, Ciampi R, Nikiforov Y, Pinchera A 2004 Identification of a novel point mutation in the RET gene (Ala883Thr), which is associated with medullary thyroid carcinoma phenotype only in homozygous condition. *J Clin Endocrinol Metab* **89**:5823–5827.
  97. McWhinney SR, Boru G, Binkley PK, Peczkowska M, Januszewicz AA, Neumann HP, Eng C 2003 Intronic single nucleotide polymorphisms in the RET protooncogene are associated with a subset of apparently sporadic pheochromocytoma and may modulate age of onset. *J Clin Endocrinol Metab* **88**:4911–4916.
  98. Borrego S, Wright FA, Fernandez RM, Williams N, Lopez-Alonso M, Davuluri R, Antinolo G, Eng C 2003 A founding locus within the RET proto-oncogene may account for a large proportion of apparently sporadic Hirschsprung disease and a subset of cases of sporadic medullary thyroid carcinoma. *Am J Hum Genet* **72**:88–100.
  99. Griseri P, Pesce B, Patrone G, Orsinga J, Pupo F, Sancandi M, Hofstra R, Romeo G, Ravazzolo R, Devoto M, Ceccherini I 2002 A rare haplotype of the RET proto-oncogene is a risk-modifying allele in hirschsprung disease. *Am J Hum Genet* **71**:969–974.
  100. Borrego S, Saez ME, Ruiz A, Gimm O, Lopez-Alonso M, Antinolo G, Eng C 1999 Specific polymorphisms in the RET proto-oncogene are over-represented in patients with Hirschsprung disease and may represent loci modifying phenotypic expression. *J Med Genet* **36**:771–774.
  101. Yip L, Cote GJ, Shapiro SE, Ayers GD, Herzog CE, Sellin RV, Sherman SI, Gagel RF, Lee JE, Evans DB 2003 Multiple endocrine neoplasia type 2: evaluation of the genotype-phenotype relationship. *Arch Surg* **138**:409–416; discussion 416.
  102. Gagel R, Marx S 2003 Multiple endocrine neoplasia. In: Larsen P, Kronenberg H, Melmed S, et al (eds) *Williams Textbook of Endocrinology*, 10th ed., Vol 1. Philadelphia, W.B. Saunders, pp. 1717–1762.
  103. Mulligan LM, Eng C, Healey CS, Clayton D, Kwok JB, Gardner E, Ponder MA, Frilling A, Jackson CE, Lehnert H, et al 1994 Specific mutations of the RET proto-oncogene are related to disease phenotype in MEN 2A and FMTC. *Nat Genet* **6**:70–74.
  104. Chabre O, Labat F, Pinel N, Berthod F, Tarel V, Bachelot I 1992 Cutaneous lesion associated with multiple endocrine neoplasia type 2A: Lichen amyloidosis or notalgia paresthetica? *Henry Ford Hosp Med J* **40**:245–248.
  105. Wong CK, Lin CS 1988 Friction amyloidosis. *Int J Dermatol* **27**:302–307.
  106. Raue F, Kraimps JL, Dralle H, Cougard P, Proye C, Frilling A, Limbert E, Llenas LF, Niederle B 1995 Primary hyperparathyroidism in multiple endocrine neoplasia type 2A. *J Intern Med* **238**:369–373.
  107. Jimenez C, Dang GT, Schultz PN, El-Naggar A, Shapiro S, Barnes EA, Evans DB, Vassilopoulou-Sellin R, Gagel RF, Cote GJ, Hoff AO 2004 A novel point mutation of the RET protooncogene involving the second intracellular tyrosine kinase domain in a family with medullary thyroid carcinoma. *J Clin Endocrinol Metab* **89**:3521–3526.
  108. Bolino A, Schuffenecker I, Luo Y, Seri M, Silengo M, Tocco T, Chabrier G, Houdent C, Murat A, Schlumberger M, et al 1995 RET mutations in exons 13 and 14 of FMTC patients. *Oncogene* **10**:2415–2419.
  109. Fink M, Weinhusel A, Niederle B, Haas OA 1996 Distinction between sporadic and hereditary medullary thyroid carcinoma (MTC) by mutation analysis of the RET proto-oncogene. “Study Group Multiple Endocrine Neoplasia Austria (SMENA).” *Int J Cancer* **69**:312–316.
  110. Nilsson O, Tisell LE, Jansson S, Ahlman H, Gimm O, Eng C 1999 Adrenal and extra-adrenal pheochromocytomas in a family with germline RET V804L mutation. *JAMA* **281**: 1587–1588.
  111. Fattoruso O, Quadro L, Libroia A, Verga U, Lupoli G, Cascone E, Colantuoni V 1998 A GTG to ATG novel point mutation at codon 804 in exon 14 of the RET proto-oncogene in two families affected by familial medullary thyroid carcinoma. *Hum Mutat* **1**:S167–171.
  112. Feldman GL, Edmonds MW, Ainsworth PJ, Schuffenecker I, Lenoir GM, Saxe AW, Talpos GB, Roberson J, Petrucelli N, Jackson CE 2000 Variable expressivity of familial medullary thyroid carcinoma (FMTC) due to a RET V804M (GTG → ATG) mutation. *Surgery* **128**:93–98.
  113. Smith DP, Houghton C, Ponder BA 1997 Germline mutation of RET codon 883 in two cases of de novo MEN 2B. *Oncogene* **15**:1213–1217.
  114. Carlson KM, Dou S, Chi D, Scavarda N, Toshima K, Jackson CE, Wells SA Jr, Goodfellow PJ, Donis-Keller H 1994 Single missense mutation in the tyrosine kinase catalytic domain of the RET protooncogene is associated with multiple endocrine neoplasia type 2B. *Proc Natl Acad Sci USA* **91**:1579–1583.
  115. Rossel M, Schuffenecker I, Schlumberger M, Bonnardel C, Modigliani E, Gardet P, Navarro J, Luo Y, Romeo G, Lenoir G, et al 1995 Detection of a germline mutation at codon 918

- of the RET proto-oncogene in French MEN 2B families. *Hum Genet* **95**:403–406.
116. Jindrichova S, Kodet R, Krskova L, Vlcek P, Bendlova B 2003 The newly detected mutations in the RET proto-oncogene in exon 16 as a cause of sporadic medullary thyroid carcinoma. *J Mol Med* **81**:819–823.
  117. Amosenko FA, Brzhezovskiy VZ, Lyubchenko LN, Shabanov MA, Kozlova VM, Vanushko VE, Kazubskaja TP, Gar'kavtseva RF, Kalinin VN 2003 Analysis of mutations of the RET proto-oncogene in patients with medullary thyroid carcinoma [in Russian]. *Genetika* **39**:847–854.
  118. Kitamura Y, Scavarda N, Wells SA, Jr, Jackson CE, Goodfellow PJ 1995 Two maternally derived missense mutations in the tyrosine kinase domain of the RET protooncogene in a patient with de novo MEN 2B. *Hum Mol Genet* **4**:1987–1988.
  119. Miyauchi A, Futami H, Hai N, Yokozawa T, Kuma K, Aoki N, Kosugi S, Sugano K, Yamaguchi K 1999 Two germline missense mutations at codons 804 and 806 of the RET proto-oncogene in the same allele in a patient with multiple endocrine neoplasia type 2B without codon 918 mutation. *Jpn J Cancer Res* **90**:1–5.
  120. Iwashita T, Murakami H, Kurokawa K, Kawai K, Miyauchi A, Futami H, Qiao S, Ichihara M, Takahashi M 2000 A two-hit model for development of multiple endocrine neoplasia type 2B by RET mutations. *Biochem Biophys Res Commun* **268**:804–808.
  121. Jimenez C, Habra MA, Huang SC, El-Naggar A, Shapiro SE, Evans DB, Cote G, Gagel RF 2004 Pheochromocytoma and medullary thyroid carcinoma: A new genotype-phenotype correlation of the RET protooncogene 891 germline mutation. *J Clin Endocrinol Metab* **89**:4142–4145.
  122. Frohnauer MK, Decker RA 2000 Update on the MEN 2A c804 RET mutation: Is prophylactic thyroidectomy indicated? *Surgery* **128**:1052–1057; discussion 1057–1058.
  123. Machens A, Niccoli-Sire P, Hoegel J, Frank-Raue K, van Vroonhoven TJ, Roehner HD, Wahl RA, Lamesch P, Raue F, Conte-Devolx B, Dralle H; European Multiple Endocrine Neoplasia (EUROMEN) Study Group 2003 Early malignant progression of hereditary medullary thyroid cancer. *N Engl J Med* **349**:1517–1525.
  124. Greene FL, Page DL, Fleming ID, Fritz A, Balch CM, Haller DG, Morrow M (eds) 2002 *AJCC Cancer Staging Manual*, 6th ed. Springer-Verlag, New York.
  125. Badner JA, Sieber WK, Garver KL, Chakravarti A 1990 A genetic study of Hirschsprung disease. *Am J Hum Genet* **46**:568–580.
  126. Fitze G, Cramer J, Ziegler A, Schierz M, Schreiber M, Kuhlisch E, Roesner D, Schackert HK 2002 Association between c135G/A genotype and RET proto-oncogene germline mutations and phenotype of Hirschsprung's disease. *Lancet* **359**:1200–1205.
  127. Seri M, Yin L, Barone V, Bolino A, Celli I, Bocciardi R, Pasini B, Ceccherini I, Lerone M, Kristoffersson U, Larsson LT, Casasa JM, Cass DT, Ambramowicz MJ, Vanderwinden JM, Kravcenkiene I, Baric I, Silengo M, Martucciello G, Romeo G 1997 Frequency of RET mutations in long- and short-segment Hirschsprung disease. *Hum Mutat* **9**:243–249.
  128. Peretz H, Luboshitsky R, Baron E, Biton A, Gershoni R, Usher S, Goyenberg E, Yacobson E, Graff E, Lapidot M 1997 Cys 618 Arg mutation in the RET proto-oncogene associated with familial medullary thyroid carcinoma and maternally transmitted Hirschsprung's disease suggesting a role for imprinting. *Hum Mutat* **10**:155–159.
  129. Cohen MS, Phay JE, Albinson C, DeBenedetti MK, Skinner MA, Lairmore TC, Doherty GM, Balfe DM, Wells SA Jr, Moley TF 2002 Gastrointestinal manifestations of multiple endocrine neoplasia type 2. *Ann Surg* **235**:648–654; discussion 654–645.
  130. Gabriel SB, Salomon R, Pelet A, Angrist M, Amiel J, For-nage M, Attie-Bitach T, Olson JM, Hofstra R, Buys C, Steffann J, Munnich A, Lyonnet S, Chakravarti A 2002 Segregation at three loci explains familial and population risk in Hirschsprung disease. *Nat Genet* **31**:89–93.
  131. Passarge E 2002 Dissecting Hirschsprung disease. *Nat Genet* **31**:11–12.
  132. Nishikawa M, Murakumo Y, Imai T, Imai T, Kawai K, Nagaya M, Funahashi H, Nakao A, Takashi M 2003 Cys611Ser mutation in RET proto-oncogene in a kindred with medullary thyroid carcinoma and Hirschsprung's disease. *Eur J Hum Genet* **11**:364–368.
  133. Borrego S, Ruiz A, Saez ME, Gimm O, Gao X, Lopez-Alonso M, Hernandez A, Wright FA, Antinolo G, Eng C 2000 RET genotypes comprising specific haplotypes of polymorphic variants predispose to isolated Hirschsprung disease. *J Med Genet* **37**:572–578.
  134. Borrego S, Eng C, Sanchez B, Saez ME, Navarro E, Antinolo G 1998 Molecular analysis of the ret and GDNF genes in a family with multiple endocrine neoplasia type 2A and Hirschsprung disease. *J Clin Endocrinol Metab* **83**:3361–3364.
  135. Fitze G, Schierz M, Kuhlisch E, Schreiber M, Ziegler A, Roesner D, Schackert HK 2003 Novel intronic polymorphisms in the RET proto-oncogene and their association with Hirschsprung disease. *Hum Mutat* **22**:177.
  136. Heshmati HM, Gharib H, van Heerden JA, Sizemore GW 1997 Advances and controversies in the diagnosis and management of medullary thyroid carcinoma. *Am J Med* **103**:60–69.
  137. Vierhapper H, Raber W, Bieglmayer C, Kaserer K, Weinhausl A, Niederle B 1997 Routine measurement of plasma calcitonin in nodular thyroid diseases. *J Clin Endocrinol Metab* **82**:1589–1593.
  138. Hennessy JF, Wells SA, Jr, Ontjes DA, Cooper CW 1974 A comparison of pentagastrin injection and calcium infusion as provocative agents for the detection of medullary carcinoma of the thyroid. *J Clin Endocrinol Metab* **39**:487–495.
  139. Melvin KE, Miller HH, Tashjian AH, Jr 1971 Early diagnosis of medullary carcinoma of the thyroid gland by means of calcitonin assay. *N Engl J Med* **285**:1115–1120.
  140. Gagel RF, Tashjian AH, Jr, Cummings T, Papathanasopoulos N, Kaplan MM, DeLellis RA, Wolfe HJ, Reichlin S 1988 The clinical outcome of prospective screening for multiple endocrine neoplasia type 2a. An 18-year experience. *N Engl J Med* **318**:478–484.
  141. Wohlk N, Cote GJ, Bugalho MM, Ordonez N, Evans DB, Goepfert H, Khorana S, Schultz P, Richards CS, Gagel RF 1996 Relevance of RET proto-oncogene mutations in sporadic medullary thyroid carcinoma. *J Clin Endocrinol Metab* **81**:3740–3745.
  142. NCCN Oncology Practice Guidelines v.2004. National Comprehensive Cancer Network. NCCN Oncology Practice Guidelines v.2004. [www.nccn.org/physician\\_gls/f\\_guidelines.html](http://www.nccn.org/physician_gls/f_guidelines.html) (Last accessed April 26, 2005).
  143. Sobol H, Narod SA, Nakamura Y, Boneu A, Calmettes C, Chaderas D, Charpentier G, Chatal JF, Delepine N, Delisle MJ 1989 Screening for multiple endocrine neoplasia type 2a with DNA-polymorphism analysis. *N Engl J Med* **321**:996–1001.

144. Shapiro SE, Cote GC, Lee JE, Gagel RF, Evans DB 2003 The role of genetics in the surgical management of familial endocrinopathy syndromes. *J Am Coll Surg* **197**:818–831.
145. Yen TW, Shapiro SE, Gagel RF, Sherman SI, Lee JE, Evans DB 2003 Medullary thyroid carcinoma: results of a standardized surgical approach in a contemporary series of 80 consecutive patients. *Surgery* **134**:890–899; discussion 899–901.
146. Buhr HJ, Kallinowski F, Raue F, Frank-Raue K, Herfarth C 1993 Microsurgical neck dissection for occultly metastasizing medullary thyroid carcinoma. Three-year results. *Cancer* **72**:3685–3693.
147. Wells SA, Jr, Chi DD, Toshima K, Dehner LP, Coffin CM, Dowton SB, Ivanovich JL, DeBenedetti MK, Dilley WG, Moley JF, et al 1994 Predictive DNA testing and prophylactic thyroidectomy in patients at risk for multiple endocrine neoplasia type 2A. *Ann Surg* **220**:237–247; discussion 247–250.
148. Gill JR, Reyes-Mugica M, Iyengar S, Kidd KK, Toulakian RJ, Smith C, Keller MS, Genel M 1996 Early presentation of metastatic medullary carcinoma in multiple endocrine neoplasia, type IIA: Implications for therapy. *J Pediatr* **129**:459–464.
149. Yip L, Lee JE, Shapiro SE, Waguespack SG, Sherman SI, Hoff AO, Gagel RF, Arens JF, Evans DB 2004 Surgical management of hereditary pheochromocytoma. *J Am Coll Surg* **198**:525–534; discussion 534–525.

Address reprint requests to:

*Douglas B. Evans, M.D.*

*Department of Surgical Oncology, Unit 444*

*The University of Texas M. D. Anderson Cancer Center*

*1400 Holcombe Boulevard*

*P.O. Box: 301402*

*Houston, TX 77230-1402*

*E-mail: devans@mdanderson.org*