

Laparoscopic resection of adrenal cortical carcinoma: A cautionary note

Ricardo J. Gonzalez, MD,^a Suzanne Shapiro, MS,^a Nicholas Sarlis, MD, PhD,^b
Rena Vassilopoulou-Sellin, MD,^b Nancy D. Perrier, MD,^a Douglas B. Evans, MD,^a
and Jeffrey E. Lee, MD,^a Houston, Tex

Background. While laparoscopic removal of small, benign, functioning adrenal tumors is accepted, laparoscopic resection of adrenal tumors that may be adrenal cortical carcinoma (ACC) remains controversial.

Methods. The records of all patients with ACC evaluated at a single institution from 1991 through 2004 were reviewed retrospectively.

Results. Among 170 patients with ACC, 153 patients underwent open anterior adrenalectomy, 6 underwent laparoscopic adrenalectomy, 1 was treated via an open flank approach, and 10 had no operation. At a median follow-up of 28 months, 115 (86%) of 133 patients who had undergone open anterior resection of primary ACC had had a recurrence. Local recurrence and peritoneal carcinomatosis were components of initial failure in 46 (35%) and 11 patients (8%), respectively. In contrast, all 6 patients who underwent laparoscopic resection of ACC had recurrences, and peritoneal carcinomatosis was a component of initial failure in 5 (83%) of them (open vs laparoscopic resection, Fisher exact test $P = .0001$).

Conclusions. Laparoscopic resection of ACC is associated with a high risk of peritoneal carcinomatosis. Open adrenalectomy remains the standard of care for patients presenting with an adrenal cortical tumor for which ACC is in the differential diagnosis. (*Surgery* 2005;138:1078-86.)

From the Departments of Surgical Oncology^a and Endocrine Neoplasia and Hormonal Disorders,^b The University of Texas M. D. Anderson Cancer Center, Houston

ADRENAL CORTICAL CARCINOMA (ACC) is a rare endocrine neoplasm with a poor prognosis. Most patients with ACC are diagnosed at an advanced stage of disease; the primary tumors usually are large and have invaded adjacent organs, even if metastatic spread to distant sites is not present. In the absence of symptoms of hypercortisolism or androgen excess, early diagnosis is uncommon.^{1,2} For patients who present with localized disease, complete operative resection remains the only potentially curative treatment. An open transabdominal approach has been the standard operative approach in these patients as it provides maximal exposure, facilitates complete resection, minimizes the risk of tumor spillage, and, when necessary, allows for vascular control of the inferior

vena cava, aorta, and renal vessels.^{2,3} In contrast, laparoscopic adrenalectomy is preferred for removal of benign, functioning adrenal tumors such as aldosteronomas and pheochromocytomas⁴ and of the rare metastasis to the adrenal gland.⁵ Controversy remains regarding laparoscopic resection of incidentally discovered adrenal cortical tumors whose differential diagnosis includes primary ACC.⁶⁻¹⁷ In an attempt to determine the oncologic safety of laparoscopic adrenalectomy for ACC, we reviewed the records of patients with ACC treated at our institution, including patients who underwent adrenalectomy before referral. Outcomes of open and laparoscopic adrenalectomy were compared to identify the frequency and patterns of tumor recurrence.

PATIENTS AND METHODS

Patients. Approval from The University of Texas M. D. Anderson Cancer Center's institutional review board was obtained for the study. The records of all patients evaluated for a diagnosis of ACC at our institution between January 1991 and November 2004 were reviewed retrospectively. Patients who underwent adrenalectomy before referral as well as patients who underwent operation at our institution

Presented at the 26th Annual Meeting of the American Association of Endocrine Surgeons, Cancun, Mexico, April 3-5, 2005.

Reprint requests: Jeffrey E. Lee, MD, Section of Endocrine Tumor Surgery, Department of Surgical Oncology, Unit 444, The University of Texas M. D. Anderson Cancer Center, 1515 Holcombe Blvd, Houston, TX 77030-4009.

0039-6060/\$ - see front matter

© 2005 Mosby, Inc. All rights reserved.

doi:10.1016/j.surg.2005.09.012

were included. Patients who did not undergo adrenalectomy because of a locally advanced, unresectable primary tumor, distant metastatic disease, comorbidities, or poor performance status precluding surgical resection were excluded from the analysis. Patients with distant metastatic disease who underwent resection of both their primary adrenal tumor and their synchronous metastatic disease, and those who underwent incomplete resection of their primary tumor (R2 resection) were included in all analyses, except the analysis of patterns of failure.

Data on patient characteristics, signs and symptoms at presentation, clinical evidence of hormone production, radiographic and histopathologic tumor size, operative treatment, patterns of failure, and patient survival were extracted from the medical records. For purposes of this analysis, recurrent disease was diagnosed on the basis of radiographic (abdominal computed tomographic [CT] scanning and/or chest radiography) and/or clinical findings, and defined as local (operative site), regional nodal (para-aortic for left-side primary tumors or paracaval for right-side primary tumors), peritoneal cavity (carcinomatosis), or distant; tissue confirmation was not required for the diagnosis of recurrent disease.

Statistical analysis. Fisher exact test was used to compare recurrence rates in patients who underwent open versus laparoscopic adrenalectomy. Student *t* test was used to compare tumor size in patients with functioning versus nonfunctioning tumors, and in patients who underwent open versus laparoscopic adrenalectomy. The Kaplan-Meier product limit method was used for overall survival and recurrence-free survival. A *P* value less than .05 was considered statistically significant.

RESULTS

Patient characteristics. Of 170 consecutive patients evaluated for ACC, 10 were excluded from this study because they did not undergo operative resection of their primary tumor owing to extensive metastatic disease at presentation (8), a locally advanced, unresectable primary tumor (1), or poor performance status and comorbidity (1). Among the remaining 160 patients, there were 109 women (68%) and 51 men (32%). The median age at diagnosis was 46 years (range, 3-78 years). The most common presenting symptoms were weight gain, abdominal or flank pain, and weakness (Table I). Clinically functioning tumors were identified in 62 patients (39%) (Table II); 98 patients (61%) had clinically nonfunctioning tumors. Among patients with functioning tumors,

Table I. Presenting signs and symptoms in 160 patients with ACC

<i>Sign or symptom</i>	<i>No. of patients (%)</i> *
Weight gain	81 (51)
Pain	75 (47)
Weakness	50 (31)
Anemia	37 (23)
Hirsutism	35 (22)
Bruising	27 (17)
Diabetes mellitus	18 (11)
Weight loss	14 (9)
Fever	10 (6)
Anorexia	6 (4)

*Percentages are greater than 100 because patients frequently presented with multiple symptoms.

Table II. Clinical hormone excess in 62 patients with functioning ACC

<i>Hormone</i>	<i>Clinical signs of hormone excess, no. of patients (%)</i>
Cortisol alone	34 (55)
Androgens alone	12 (19)
Estrogens alone	1 (2)
Aldosterone alone	2 (3)
Cortisol plus androgens	8 (13)
Cortisol plus aldosterone	3 (5)
Androgens plus aldosterone	2 (3)

mixed hormone production was present in 13 patients (21%).

Tumor characteristics. There were 94 patients (59%) with right-side tumors and 66 patients (41%) with left-side tumors. Radiographic data from CT or magnetic resonance imaging documenting primary adrenal tumor size were available for 84 (52%) of 160 patients. The median radiographic primary tumor size was 10 cm (range, 3-21 cm). Pathologic confirmation of the size of the resected primary tumor was available for 118 patients (74%); the median size of the resected tumors was 13 cm (range, 2-30 cm). Six resected tumors (5%) were less than or equal to 5 cm, and 112 (95%) were greater than 5 cm. There was no difference in mean or median tumor size between functioning and nonfunctioning tumors. Patients who underwent laparoscopic resection of primary adrenal cortical carcinoma via an open anterior adrenalectomy (133 patients) had a median tumor size of 13 cm, while patients who underwent laparoscopic adrenalectomy (6 patients) had a median tumor size of 6 cm (*P* = .0003).

Operative treatment of ACC. Figure 1 outlines the operative treatment of all the patients. Among

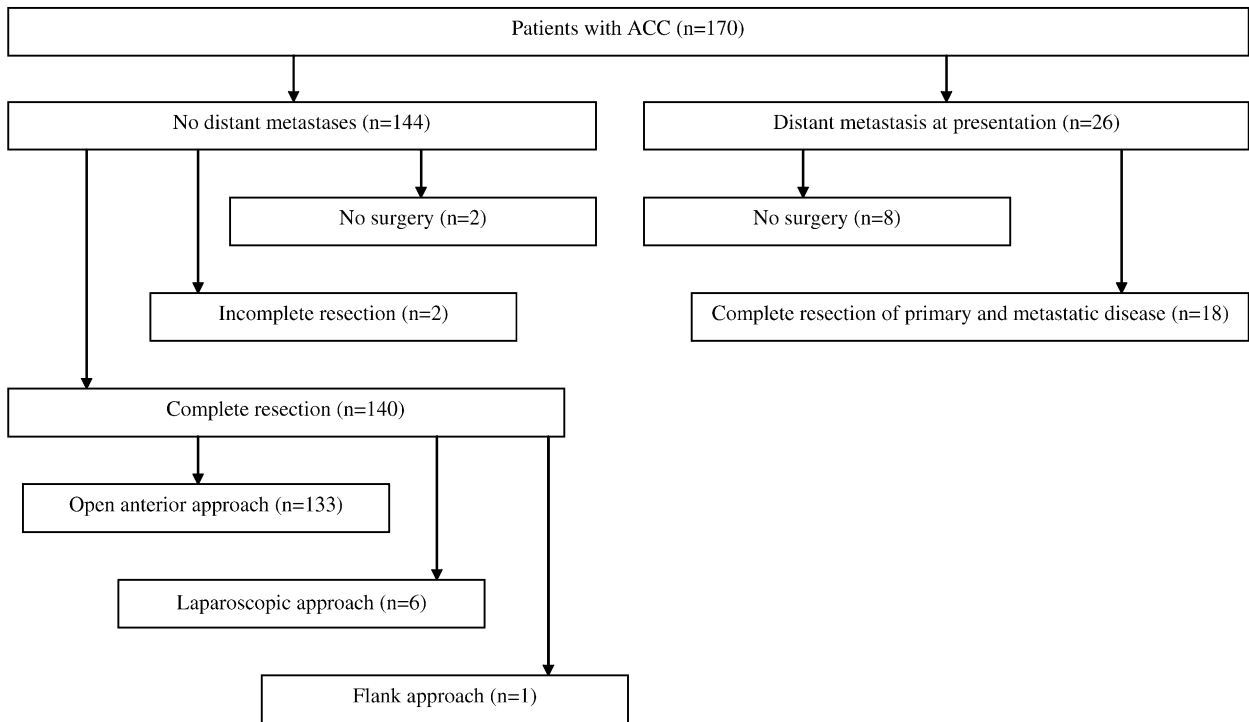


Fig 1. Surgical management of 160 consecutive patients with ACC (adrenal cortical carcinoma).

160 patients who underwent operative resection, 142 had local-regional disease only, and 18 had distant metastatic disease at presentation. All patients with distant metastasis at presentation who had been operated on underwent complete resection of both their primary tumors and their metastatic disease. In 14 patients, synchronous resection of the primary tumor and the metastatic disease was performed, while 4 patients underwent resection of the primary tumor followed by staged resection of the metastases. Patients who underwent adrenalectomy in the setting of extra-adrenal metastatic disease were excluded from the analysis of patterns of failure and survival. Seventeen patients in this series underwent operative resection of their primary tumors at University of Texas M. D. Anderson; the remaining 143 patients underwent their primary operation before referral.

Open adrenalectomy for primary ACC. An open anterior approach to resection of the primary adrenal tumor was performed in 153 of 160 patients (Fig 2). Among these patients, resection was confined to the adrenal gland in 98 (64%). In 27 patients, both the involved adrenal gland and the ipsilateral kidney were resected, and 19 additional patients had a multivisceral resection that included the involved adrenal gland, the ipsilateral kidney, and at least one other organ. Hepatic resection was required in 8 patients, 5 patients

required partial pancreatectomy, and 5 patients required either tumor thrombectomy or formal resection and reconstruction of the inferior vena cava. In 2 patients, the operative record clearly indicated that an incomplete resection of the primary tumor had been performed (R2 resection). These 2 patients were excluded from the analysis of patterns of local-regional recurrence and survival, as was a single patient who underwent resection of his primary tumor via a lateral flank approach.

Laparoscopic adrenalectomy for primary ACC. Six patients underwent attempted resection of their primary ACC via laparoscopy (Table III). All patients managed by this approach were referred to M. D. Anderson after their initial operative treatment. Four of the 6 patients presented with clinically functioning tumors. All 6 patients had radiographically heterogeneous tumors atypical for benign adrenal cortical adenomas. In 1 patient, tumor fracture occurred during attempted bag extraction of the resected specimen. In another patient, attempted laparoscopic resection of an 8-cm ACC had to be converted to an open procedure when uncontrolled hemorrhage occurred. The remaining 4 patients underwent an uncomplicated laparoscopic adrenalectomy. All 6 patients had tumor confined to the adrenal gland, and no patient required adjacent organ resection.

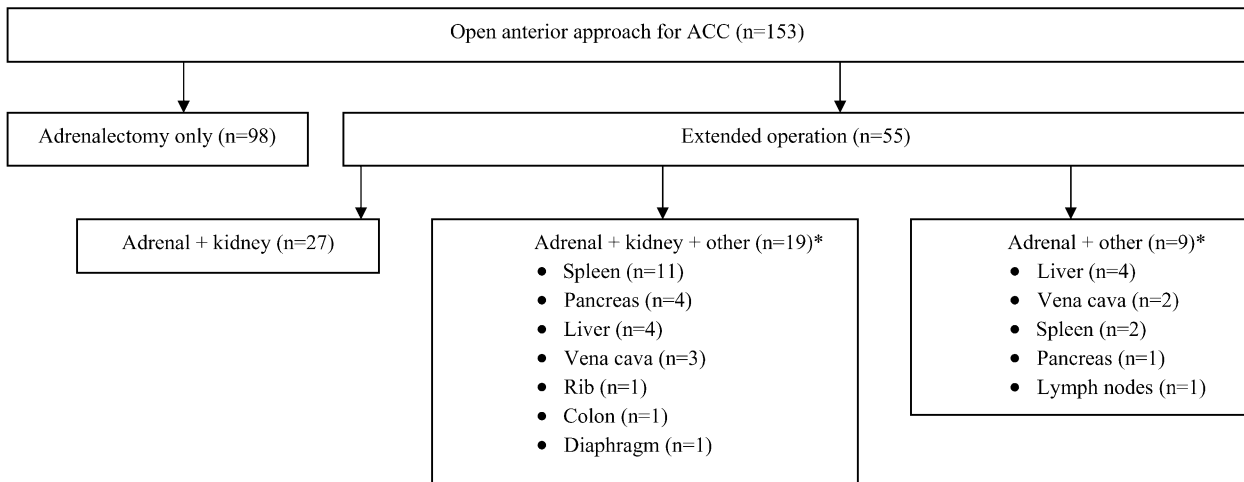


Fig 2. Open anterior surgical procedures in 153 patients with ACC (adrenal cortical carcinoma). *Patients had multiorgan resections, so the total number of organs resected is greater than the number of patients.

Table III. Clinical presentation, tumor characteristics, and patterns of recurrence and survival in 6 patients who underwent laparoscopic adrenalectomy for ACC

Patient	Signs and symptoms	Hormone production	Side	Size (cm)	Surgical complications	Site(s) of first recurrence	Status (months of follow-up)
1	Weight gain, hirsutism	Cortisol	Left	6	None described	Peritoneal	Dead (19)
2	Weight gain	Cortisol	Left	3	Tumor fracture	Local, peritoneal, distant	Dead (2)
3	Hirsutism, bruising	Cortisol	Right	6	None described	Distant	Dead (13)
4	Weight gain	None	Left	5	None described	Nodal, peritoneal, distant	Dead (15)
5	Weight gain, hypertension	Cortisol	Right	4	None described	Local, nodal, peritoneal	AWD (15)
6	Weight gain, pain	None	Right	8	Bleeding*	Local, peritoneal	AWD (29)

AWD, Alive with disease.

*Laparoscopic adrenalectomy converted to an open procedure because of uncontrolled hemorrhage.

Table IV. Patterns of recurrence in patients who underwent open anterior or laparoscopic adrenalectomy for primary ACC*

Surgical approach	Initial sites of recurrence				All sites of recurrence				
	Local	Nodal	Peritoneal	Distant	Local	Nodal	Peritoneal	Distant	Total
Open anterior (n = 133)	46 (35)	13 (10)	11 (8)	32 (24)	51 (38)	16 (12)	17 (13)	99 (74)	115 (86)
Laparoscopic (n = 6)	3 (50)	2 (33)	5 (83)	3 (50)	3 (50)	2 (33)	5 (83)	4 (67)	6 (100)

*Data are numbers of patients (%).

Patterns of recurrence and survival after operation for primary ACC. Patterns of recurrence were compared in the 133 patients who underwent resection of primary ACC via an open anterior approach and the 6 patients who underwent

laparoscopic adrenalectomy (Table IV). At a median follow-up of 28 months, 18 patients (14%) in the open anterior adrenalectomy group had not had a recurrence, 32 (24%) were alive with recurrent disease, and 83 (62%) had died. Local

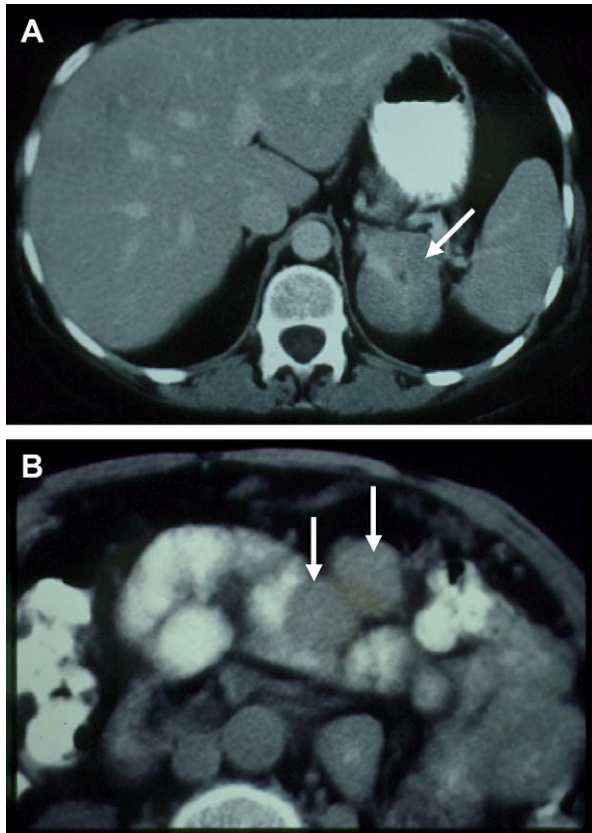


Fig 3. Abdominal CT images of a 43-year-old woman with ACC. (Table III, patient 1). The patient presented with Cushing's syndrome and a 6-cm left adrenal mass (A, arrow). A laparoscopic left adrenalectomy was performed. Cushing's syndrome recurred 7 months post-operatively. Repeat CT documented the presence of multiple intraperitoneal recurrences (B, arrows).

recurrence was a component of initial failure in 46 patients (35%), and peritoneal carcinomatosis was a component of initial failure in 11 (8%).

All 6 patients who underwent laparoscopic resection of ACC had recurrences, and 4 died. Among patients who underwent a laparoscopic resection, local recurrence was a component of initial failure in 3 patients (50%), and peritoneal carcinomatosis (Fig 3) was a component of initial failure in 5 (83%; open vs laparoscopic resection, $P = .0001$). There were no port site recurrences in the laparoscopic resection group.

Ninety-nine (74%) of the 133 patients who underwent an open anterior resection developed distant metastases. The most common sites of distant metastasis in this group were lung (51 patients, 52%), liver (33, 33%), and bone (11, 11%). The median disease-free survival duration for the open anterior resection group was 13

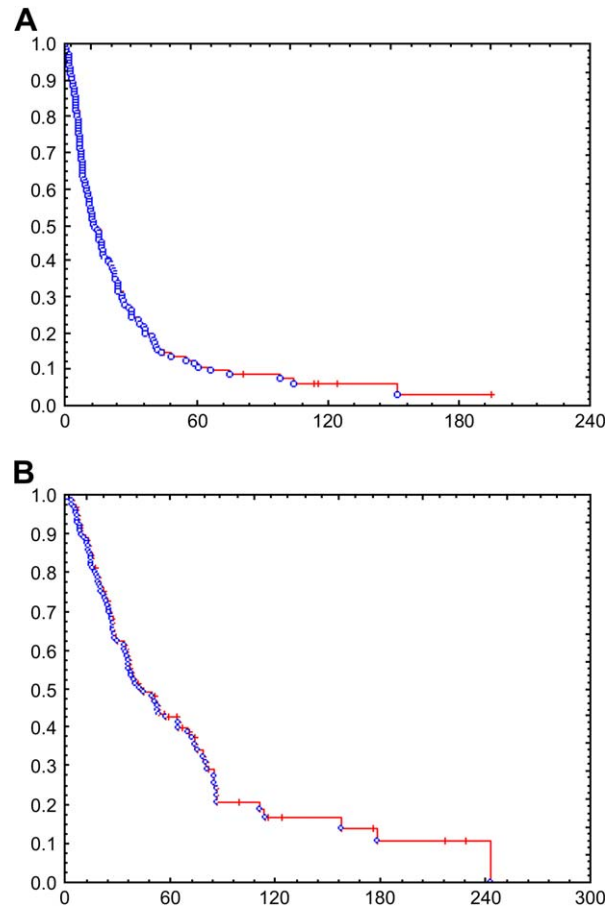


Fig 4. Disease-free (A) and overall (B) survival of 133 patients who underwent resection of primary ACC via an open anterior approach. The median disease-free survival duration was 13 months, and the median overall survival duration was 43 months.

months (Fig 4, A) and the median overall survival duration was 43 months (Fig 4, B).

We identified 6 patients in the open adrenalectomy group who had tumors 6 cm or smaller. After a median follow-up of 21 months, 4 of 6 patients were alive without recurrence, 1 was alive with disease, and 1 had died.

Among the 16 patients who developed an isolated local recurrence as their first site of failure after an open anterior resection, the median overall survival duration was 70 months. At a median follow-up of 59 months, 8 of these 16 patients had died of ACC, 7 were alive with disease, and 1 remained disease-free 11 months after re-resection of his local recurrence.

DISCUSSION

While there is consensus that laparoscopy is preferred over an open anterior operation for the

Table V. Reports of recurrence following laparoscopic adrenalectomy for ACC

First author	Institution/ location	Year	No. of patients				Follow-up (months)
			Total with ACC	Local recurrence	Peritoneal recurrence	Distant recurrence	
Ushiyama ⁷	Hamamatsu, Japan	1997	1	1	0	0	19
Hamoir ⁹	Liege, Belgium	1998	1	0	1	0	6
Foxius ⁸	Louvain, Belgium	1999	1	0	1	0	6
Valeri ¹⁰	Firenze, Italy	2002	1	1	NR	NR	8
Porpiglia ¹¹	Orbassano, Italy	2002	4	0	0	NR	19*
MacGillivray ¹²	Maine Medical Center	2002	1	0	0	1	42
Henry ¹³	Marseilles, France	2002	6	0	0	1	28*
Kebebew ¹⁴	UCSF	2002	6†	2	NR	1	40‡
Zeh ¹⁵	Johns Hopkins	2003	4	1	NR	1	24*
Prager ¹⁶	University of Vienna	2004	2	0	0	0	60, 27
Moinzadeh ¹⁷	Cleveland Clinic	2005	6	2	NR	NR	21
Current series	MDACC	2005	6	3	5	4	15*
Total	—	—	39	10/39 (26%)	7/22 (32%)	8/28 (29%)	—

ACC, Adrenal cortical carcinoma; MDACC, The University of Texas M. D. Anderson Cancer Center; NR, not reported; UCSF, University of California, San Francisco.

*Median.

†One case converted to open resection after diagnostic laparoscopy.

‡Mean.

resection of small, benign adrenal tumors, there is controversy regarding the appropriateness of laparoscopy for the resection of adrenal cortical tumors of uncertain malignant potential, including adrenal incidentalomas. While some authors have argued that laparoscopic adrenalectomy can be performed safely in selected patients with potentially malignant cortical tumors,^{6,12,13,16,17} others have urged caution, in part, on the basis of anecdotal experience with high rates of local-regional recurrence including the development of carcinomatosis.^{7-9,14}

Prior reports of laparoscopic adrenalectomy for ACC have been hampered by small patient numbers and limited follow-up (Table V).⁷⁻¹⁷ In addition, there are relatively few data regarding patterns of local and regional failure in patients with ACC who undergo a traditional open anterior resection (Table VI).¹⁸⁻²¹ Despite incomplete reporting, there are at least 2 independent reports of the rapid development of peritoneal carcinomatosis after laparoscopic adrenalectomy for adrenal cortical carcinoma (Table V).^{8,9}

In this study, we examined recurrence and survival in a large, consecutive series of patients with ACC who underwent resection via an open anterior approach. These patients represent a referral population and are biased toward patients

with advanced and recurrent disease. Most patients underwent resection of their primary tumor before referral to our center, suggesting that most general surgeons will operate on an adrenal neoplasm rather than refer such patients to a specialty center. Examination of patterns of failure and survival in this patient population illustrates several important concepts. First, local recurrence remains a significant problem in patients presenting with localized, nonmetastatic ACC; 35% of patients with resectable primary tumors suffered a local recurrence as an initial site of failure, and 38% of patients ultimately experienced a local recurrence (Table IV). Second, despite the high local recurrence rate and short disease-free survival duration (median, 13 months) of the entire group, the subset of patients with a relatively small ACC (6 cm or less) who underwent an open operation did relatively well (4 of 6 without disease at 21 months). These data stand in contrast to the uniformly poor outcome of the laparoscopic group, and they suggest that some patients with small primary tumors may do well after open resection. Third, the subset of patients who experienced an isolated local recurrence after an open anterior resection experienced a relatively long overall survival duration (median, 70 months). These data suggest that local recurrence may be related more to

Table VI. Reports of recurrence following open anterior resection of primary ACC

First author	Institution/ location	Year	No. of patients				Survival duration (mo)
			Total with ACC	Local recurrence	Peritoneal recurrence	Distant recurrence	
Icard ¹⁸	Paris, France	1992	121	41	NR	64	42%*
Pommier ¹⁹	MSKCC	1992	49	NR	8	39	28†
Crucitti ²⁰	Rome, Italy	1996	91	14	NR	NR	28†
Khorrman-Manesh ²¹	Goteborg, Sweden	1998	18	6	NR	12	29‡
Prager ¹⁶	University of Vienna	2004	8	1	NR	NR	15‡
Current series	MDACC	2005	133	51	17	99	43‡
Total	—	—	420	113/371 (30%)	25/182 (14%)	214/321 (67%)	—

ACC, Adrenal cortical carcinoma; MDACC, The University of Texas M. D. Anderson Cancer Center; MSKCC, Memorial Sloan-Kettering Cancer Center; NR, not reported.

*5-year actuarial survival (%).

†Mean.

‡Median.

inadequate primary operation (even when an open resection is performed) than to particularly aggressive tumor biology. Surgeons operating on patients with primary ACC must be prepared to resect adjacent organs (kidney, spleen, liver, pancreas, and/or vena cava) to completely remove the tumor. In addition, the prolonged survival duration in some patients with local recurrences argues in favor of reoperation in selected patients with a technically resectable local recurrence, a favorable disease-free interval, an acceptable performance status, and no evidence of distant metastatic disease.

We compared patterns of recurrence in patients who underwent an open operation with those in 6 patients who underwent laparoscopic adrenalectomy (all laparoscopic adrenalectomies were performed before referral to our center). The primary finding was a very high rate of peritoneal carcinomatosis as an initial site of failure in the patients who underwent laparoscopic adrenalectomy (83%), compared with the patients who underwent an open anterior resection (8%, $P = .0001$). Patients who underwent laparoscopic adrenalectomy uniformly developed recurrent ACC, despite having small primary tumors confined to the adrenal gland, in contrast to many of the patients who underwent open adrenalectomy. Technical issues related to laparoscopy such as tumor fracture and resulting peritoneal contamination may have contributed to the high rate of peritoneal carcinomatosis in the laparoscopy group. Primary ACCs typically are soft tumors; they are friable and easily fractured. Standard laparoscopic techniques utilize traction and countertraction on the tumor to allow adequate dissection from surrounding structures

and to expose the adrenal vein for safe ligation; it is difficult to accomplish this without causing capsular disruption and peritoneal contamination.

The results reported herein strongly suggest that open adrenalectomy should remain the standard of care for resection of adrenal cortical neoplasms for which ACC remains in the differential diagnosis. Such tumors include those with imaging characteristics suggestive of malignancy (eg, heterogeneous or irregular borders) or a transverse diameter greater than 4 cm.⁴ We realize that the application of these principles will result in some patients with relatively large but benign adrenal cortical adenomas undergoing an open, rather than laparoscopic, adrenalectomy. However, with such a potentially lethal malignancy, the morbidity associated with the presence of an abdominal incision may be relatively insignificant, compared with the oncologic importance of performing a complete tumor resection without peritoneal dissemination.

REFERENCES

1. Lee JE, Berger DH, El-Naggar AK, et al. Surgical management, DNA content, and patient survival in adrenal cortical carcinoma. *Surgery* 1995;118:1090-8.
2. Dackiw APB, Lee JE, Gagel RF, et al. Adrenal cortical carcinoma. *World J Surg* 2001;25:914-26.
3. Henley DJ, vanHeerden JA, Grant CS, et al. Adrenal cortical carcinoma—a continuing challenge. *Surgery* 1983;94:926-30.
4. Barnett CC Jr, Varma DG, El-Naggar AK, et al. Limitations of size as a criterion in the evaluation of adrenal tumors. *Surgery* 2000;128:973-82.
5. Lenert JT, Barnett CC, Kudelka AP, et al. Evaluation and surgical resection of adrenal masses in patients with a history of extra-adrenal malignancy. *Surgery* 2001;130:1060-7.

6. Heniford BT, Arca MJ, Walsh RM, et al. Laparoscopic adrenalectomy for cancer. *Semin Surg Oncol* 1999;16:293-306.
7. Ushiyama T, Suzuki K, Kageyama S, et al. A case of Cushing's syndrome due to adrenocortical carcinoma 19 months after laparoscopic adrenalectomy. *J Urol* 1997;157:2239.
8. Foxius A, Ramboux A, Lefebvre Y, et al. Hazards of laparoscopic adrenalectomy for Conn's syndrome: When enthusiasm turns to tragedy. *Surg Endosc* 1999;13:715-7.
9. Hamoir E, Meurisse M, Defechereux T. [Is laparoscopic resection of a malignant corticoadrenaloma feasible? Case report of early, diffuse and massive peritoneal recurrence after attempted laparoscopic resection.] *Ann Chir* 1998;52:364-8.
10. Valeri A, Borrelli A, Presenti L, et al. The influence of new technologies on laparoscopic adrenalectomy. Our personal experience with 91 patients. *Surg Endosc* 2002;16:1274-9.
11. Porpiglia F, Destefanis P, Fiori C, et al. Does adrenal mass size really affect safety and effectiveness of laparoscopic adrenalectomy? *Urology* 2002;60:801-5.
12. MacGillivray DC, Whalen GF, Malchoff CD, et al. Laparoscopic resection of large adrenal tumors. *Ann Surg Oncol* 2002;9:480-5.
13. Henry JF, Sebag F, Iacobone M, et al. Results of laparoscopic adrenalectomy for large and potentially malignant tumors. *World J Surg* 2002;26:1043-7.
14. Kebebew E, Siperstein AE, Clark OH, et al. Results of laparoscopic adrenalectomy for suspected and unsuspected malignant adrenal neoplasms. *Arch Surg* 2002;137:948-53.
15. Zeh HJ, Udelsman R. One hundred laparoscopic adrenalectomies: A single surgeon's experience. *Ann Surg Oncol* 2003;10:1012-7.
16. Prager G, Heinz-Peer G, Passler C, et al. Applicability of laparoscopic adrenalectomy in a prospective study in 150 consecutive patients. *Arch Surg* 2004;139:46-9.
17. Moinzadeh A, Gill IS. Laparoscopic radical adrenalectomy for malignancy in 31 patients. *J Urol* 2005;173:519-25.
18. Icard P, Chapuis Y, Andreassian B, et al. Adrenal cortical carcinoma in surgically treated patients: A retrospective study on 156 cases by the French Association of Endocrine Surgery. *Surgery* 1992;112:972-80.
19. Pommier RF, Brennan MF. An eleven-year experience with adrenocortical carcinoma. *Surgery* 1992;112:963-71.
20. Crucitti F, Bellantone R, Ferrante A, et al. The Italian Registry for Adrenal Cortical Carcinoma: Analysis of a multi-institutional series of 129 patients. The ACC Italian Registry Study Group. *Surgery* 1996;119:161-70.
21. Khorram-Manesh A, Ahlman H, Jansson S, et al. Adrenocortical carcinoma: Surgery and mitotane for treatment and steroid profiles for follow-up. *World J Surg* 1998;22:605-12.

DISCUSSION

Dr William B. Inabnet, III (New York, New York). This is very controversial. My comment is regarding the analysis that you utilized. In the open group, there were 51 patients who underwent adrenalectomy with removal of at least one other organ and 83 patients who underwent adrenalectomy alone. I think a more fair comparison would be the 6 laparoscopic patients versus the 83 adrenal-only patients because if the decision was made preoperatively to remove another organ, the surgeon would not attempt a laparoscopic resection.

Regarding the technique of laparoscopic adrenalectomy, were these performed transabdominally or retroperitoneally? Secondly, is there a way to assess the skill level of the surgeon? Rather than criticize the technique itself, it might be the technique of an inexperienced adrenal and laparoscopic surgeon. Was laparoscopic ultrasound used during these adrenal operations to determine feasibility of laparoscopic resection?

Dr Gonzalez. We opted to compare the laparoscopic group with patients in the open group who had, as you have seen, larger tumors and more aggressive local disease, erring on the side that the open group would potentially do worse.

With regard to your question about monitoring a surgeon's experience and tracking technique over time, since this is a very rare disease it would be difficult for any single surgeon in our opinion to develop sufficient experience to become proficient at safe laparoscopic resection of ACC using currently available laparoscopic techniques.

None of these patients underwent laparoscopically directed intraoperative ultrasound.

Dr Steven K. Libutti (Bethesda, Maryland). I enjoyed your paper because the topic is an important one. As we have all become more comfortable with the laparoscopic approach for adrenalectomy for benign functional and nonfunctional neoplasms, it is obvious that questions are arising whether or not this technique can be applied to the management of malignant adrenal disease. So any papers that come out on that subject are very important because they are going to supply us with our data set for moving forward with recommendations.

The question I have for you is that the group at M. D. Anderson is very experienced with doing the open resection for adrenal cortical carcinoma, and the data and the outcomes from those resections are reflective of a group with technical expertise. However, to compare that data set to 6 patients that were operated on at different institutions and ultimately referred to M. D. Anderson, I think is stacking the deck against the technique of laparoscopic adrenalectomy. And it reminds me of the adage, "Guns don't kill, people kill." I wonder if there might be a better way to do that comparison and whether or not laparoscopic approaches to adrenal cortical cancer are ever pursued at M. D. Anderson, and there might be a more uniform data set for us to perform the comparison between the 2 techniques?

Dr Gonzalez. Laparoscopic adrenalectomy is performed frequently at M. D. Anderson for small, benign adrenal neoplasms, including functioning adrenal cortical adenomas such as aldosteronomas as well as pheochromocytomas. However, we do not perform laparoscopic adrenalectomy for adrenal tumors that could be ACC. We include in that category adrenal cortical tumors that are 4 centimeters or greater in diameter, as well as those that are radiographically heterogeneous or those that exhibit irregular borders.

Dr Herbert Chen (Madison, Wisconsin). My understanding is those 6 patients with laparoscopic

adrenalectomy were performed at an outside institution. If you compare those 6 patients to patients in your open group who underwent their adrenalectomy at an outside institution as well, you might find that the incidence of peritoneal metastases may be similar, reflecting the technique of the surgeon rather than the technique overall.

Dr Gonzalez. The majority of patients in the open adrenalectomy group underwent primary tumor resection at an outside institution rather than at U. T. M. D. Anderson Cancer Center. Therefore, the comparison of the laparoscopic group (all of whom had surgery prior to referral) with the open group is actually quite fair in this regard.

Dr Quan-Yang Duh (San Francisco, California). This is a controversial issue. I share some concern about patient selection bias. I do agree with your conclusion that it is most likely a technical problem. It does not necessarily mean that the technique should not be used. It means that the people that are using the technique may not know how to use it appropriately. Historically, a laparoscopic colectomy for colon cancer took 10 years to be accepted. The earlier data showed trocar site recurrence, which became a nonissue with experience. There may not be something wrong with the technique itself, but with people not knowing how to do the operation.

Dr Gonzalez. Surgical techniques used in laparoscopic adrenalectomy are different from those used in open adrenalectomy. It is clear that the patients reported here who underwent laparoscopic adrenalectomy had a pattern of failure different from that of patients who recurred following an open operation: The laparoscopic patients presented with carcinomatosis very early, within 2 to 6 months in most patients, after their operation. I understand what you are saying, that it may potentially be the technique of the individual surgeon rather than the laparoscopic procedure itself. However, given the

very rare nature of ACC, it is going to be hard to provide an adequate population of patients to provide an acceptable "learning curve" to perfect an individual surgeon's technique for safe laparoscopic resection of ACC.

Dr Duh. A follow-up question. Right now if a 3-centimeter lesion is to be removed at M. D. Anderson and it is potentially a cancer, you would do it open. Is that correct?

Dr Gonzalez. If it is a 3-centimeter adrenal nodule and it has irregular borders or it is heterogeneous on the cross-sectional imaging, then at our institution that patient will undergo an open adrenalectomy, rather than a laparoscopic resection. Data regarding radiographic findings that predicted malignancy in small ACC from our institution was presented at the Millennium Meeting of the AAES in London in 2000.

Dr Scott Wilhelm (Cleveland, Ohio). Since all resections were performed at outside hospitals and they had such early recurrences, did your group go back and review any of the preoperative imaging from the outside studies, mainly to see exactly what these tumors looked like? Second, did they see any signs of peritoneal carcinomatosis? Did your group review the outside pathology to see whether or not when the resection was done that the capsule was invaded? Did they come across part of the gland and not know it?

Dr Gonzalez. We reviewed all of those data points. They were captured in our database and thoroughly evaluated; the imaging studies from the outside institutions were reviewed, and the outside pathology was reconfirmed at our institution by our pathologists.

Dr Wilhelm. Did you see any unusual changes in either the preop imaging or the resection specimens themselves?

Dr Gonzalez. No.